

# 113年度高病原性禽流感 禽場肉眼與組織病變

國立屏東科技大學 獸醫學系

陳雅媚 助理教授

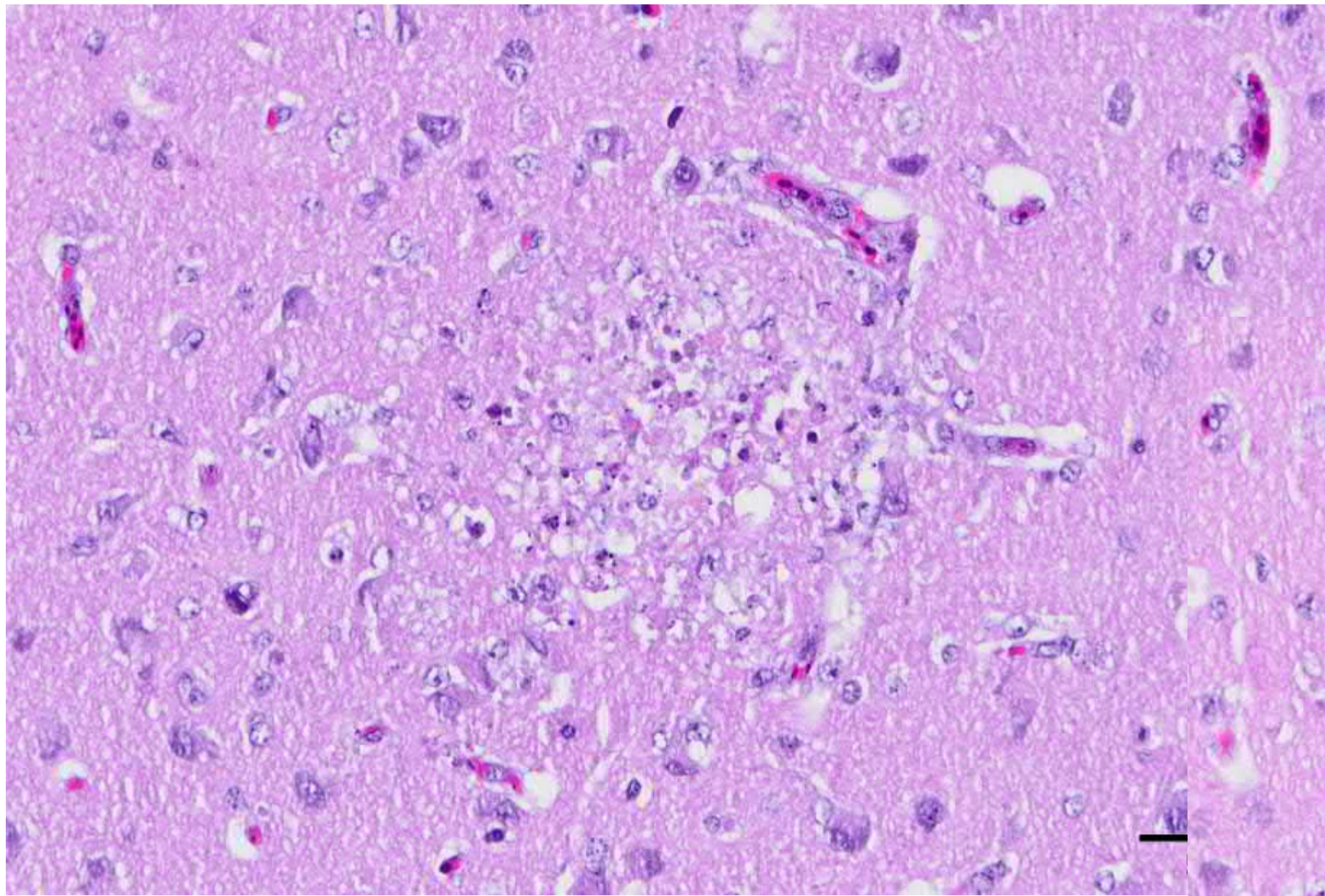
113年04月30日

# Results

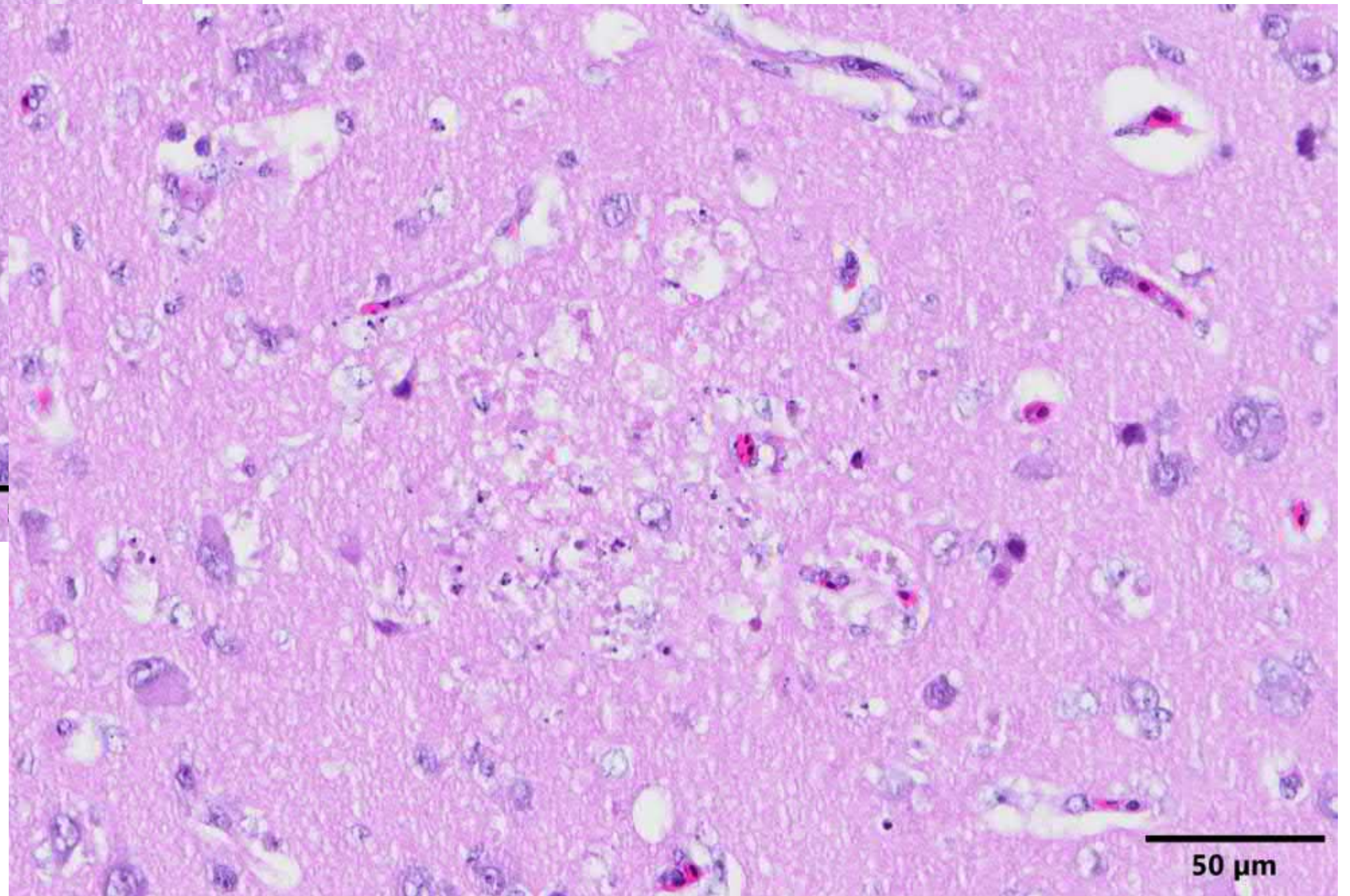
- 112年10月1日至113年3月7日，共計21場病例。
  - 雞(紅羽土雞、黑羽土雞、皇金雞、蛋雞)13例
  - 鵝(種鵝、肉鵝) 4例
  - 鴨(肉鴨) 3例
  - 鸕鶿 1例

# 雞

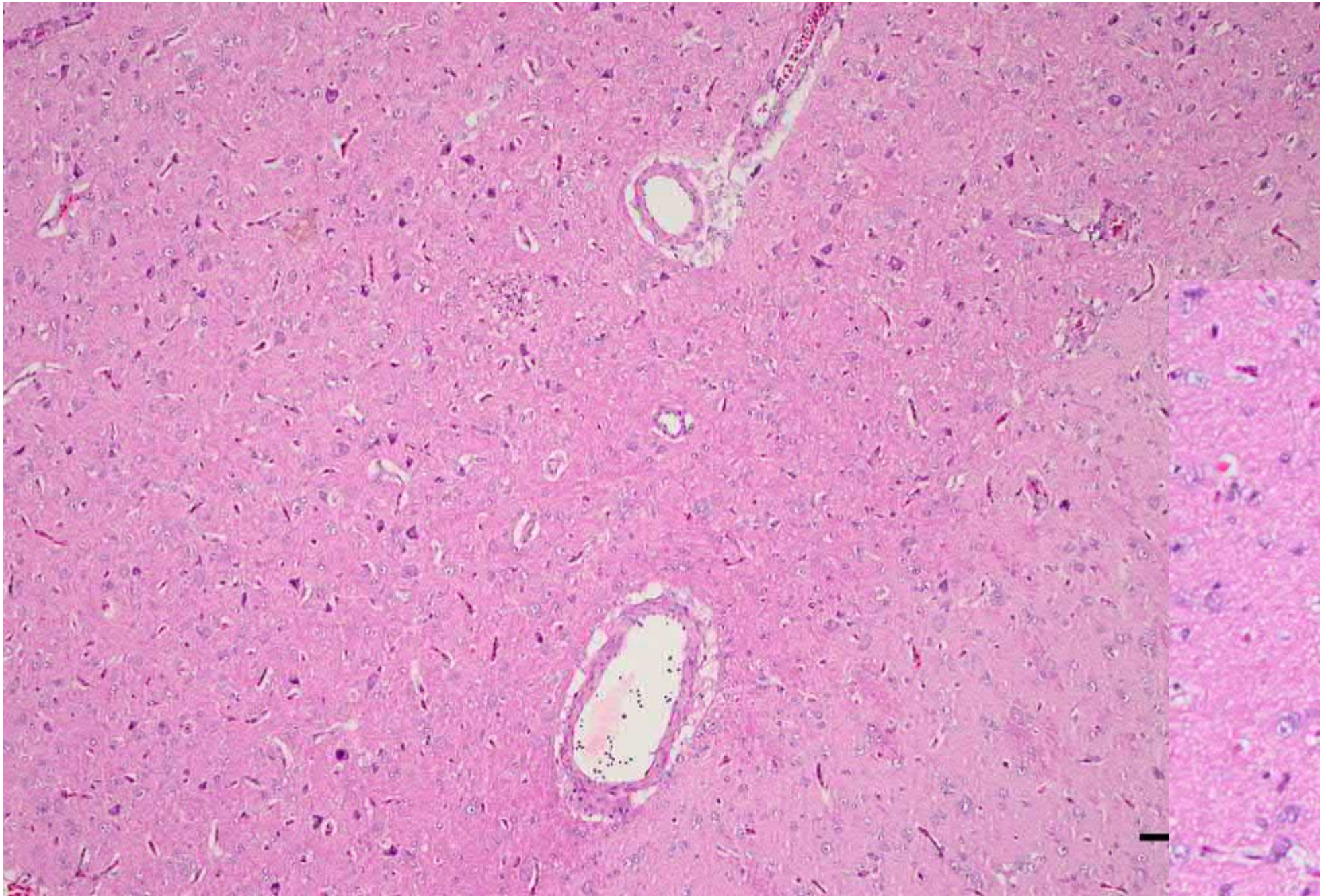
- 臨床症狀與外觀: 精神沉鬱、偶見腳脛潮紅以及神經症狀
- 肉眼病變: 腦血管怒張、心臟塌陷、心囊積液、心外膜斑駁、腎腫大、肌腺胃黏膜糜爛、胰臟出血、肌肉出血



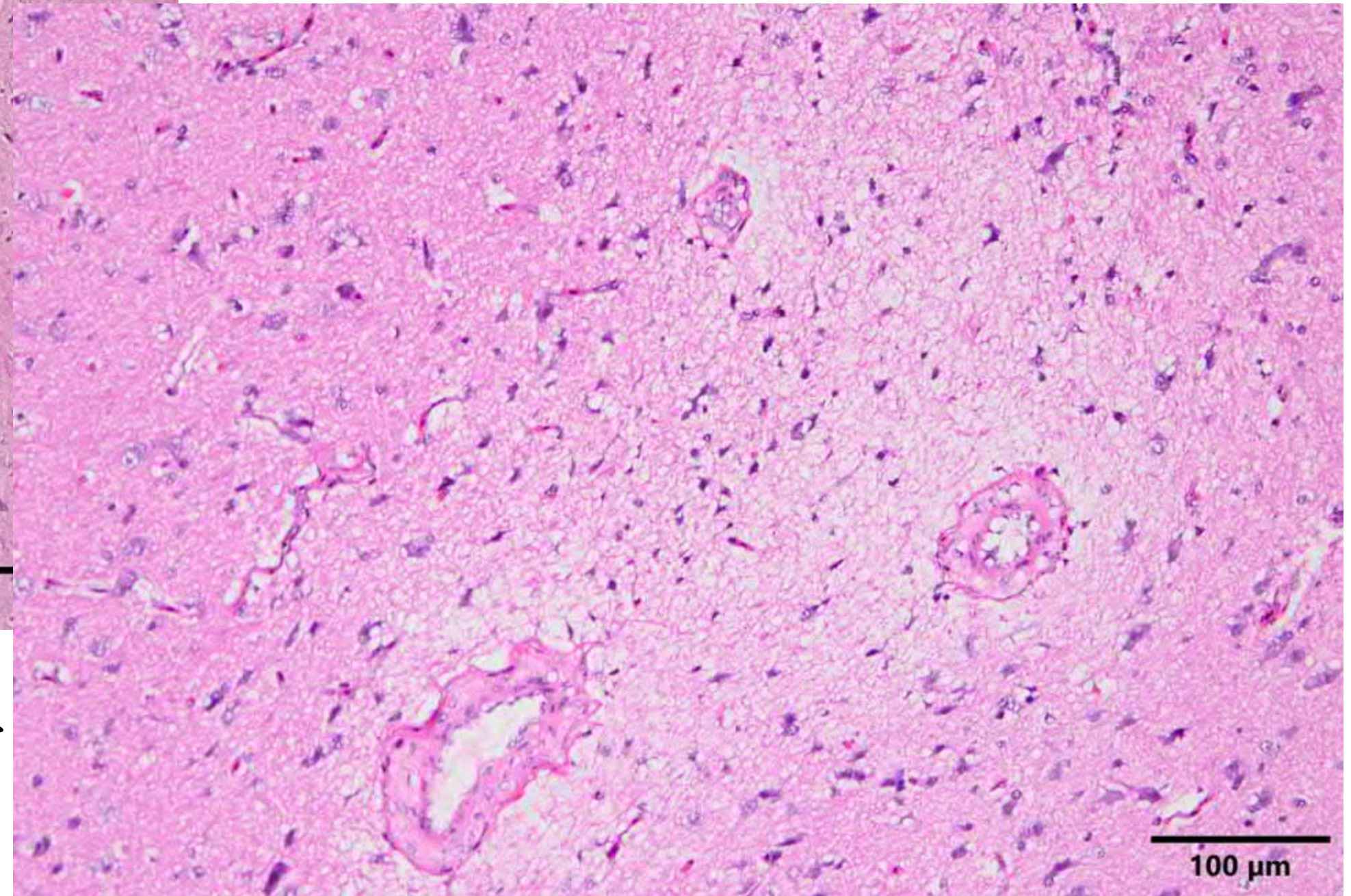
大腦實質：局部壞死



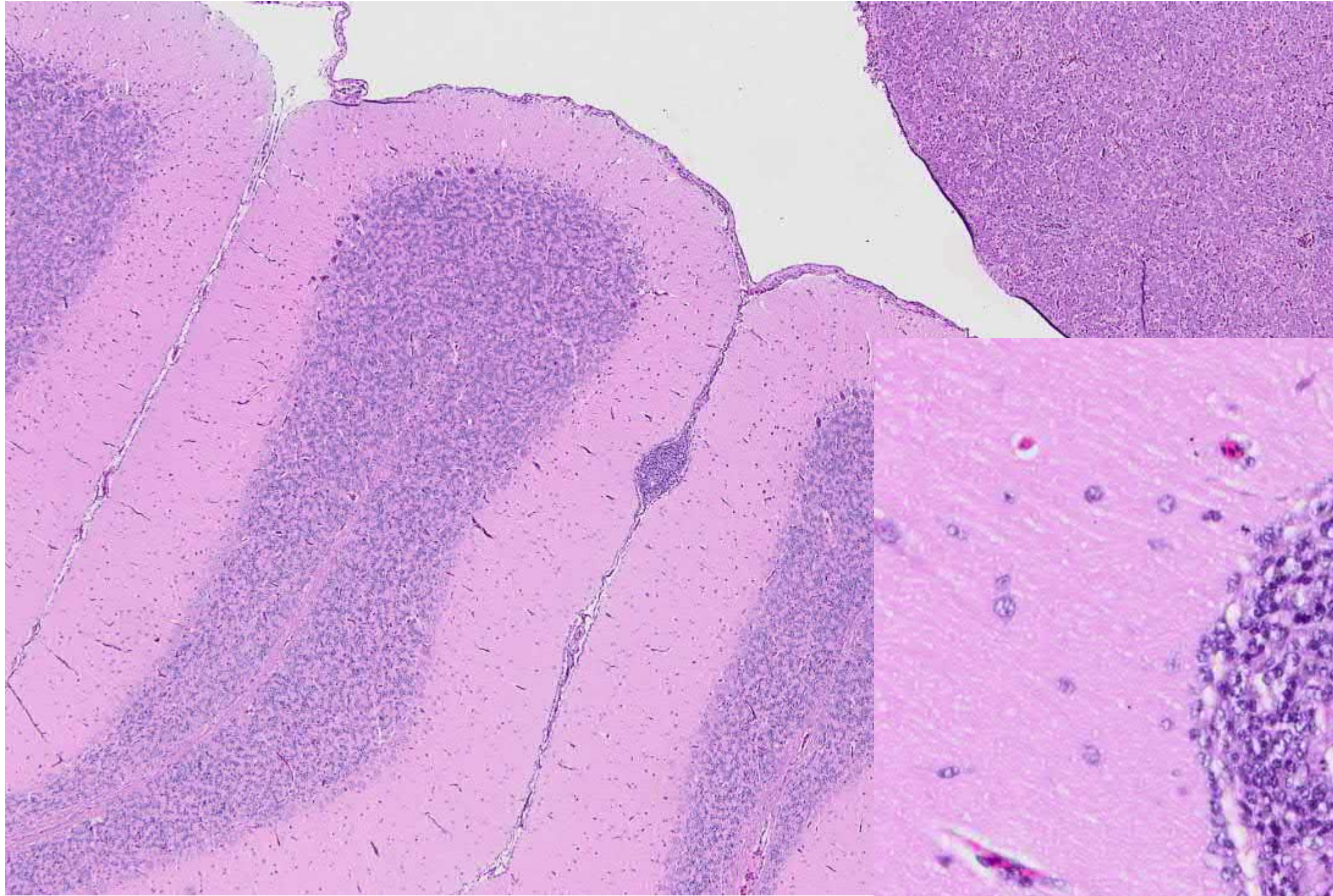
大腦實質：局部壞死



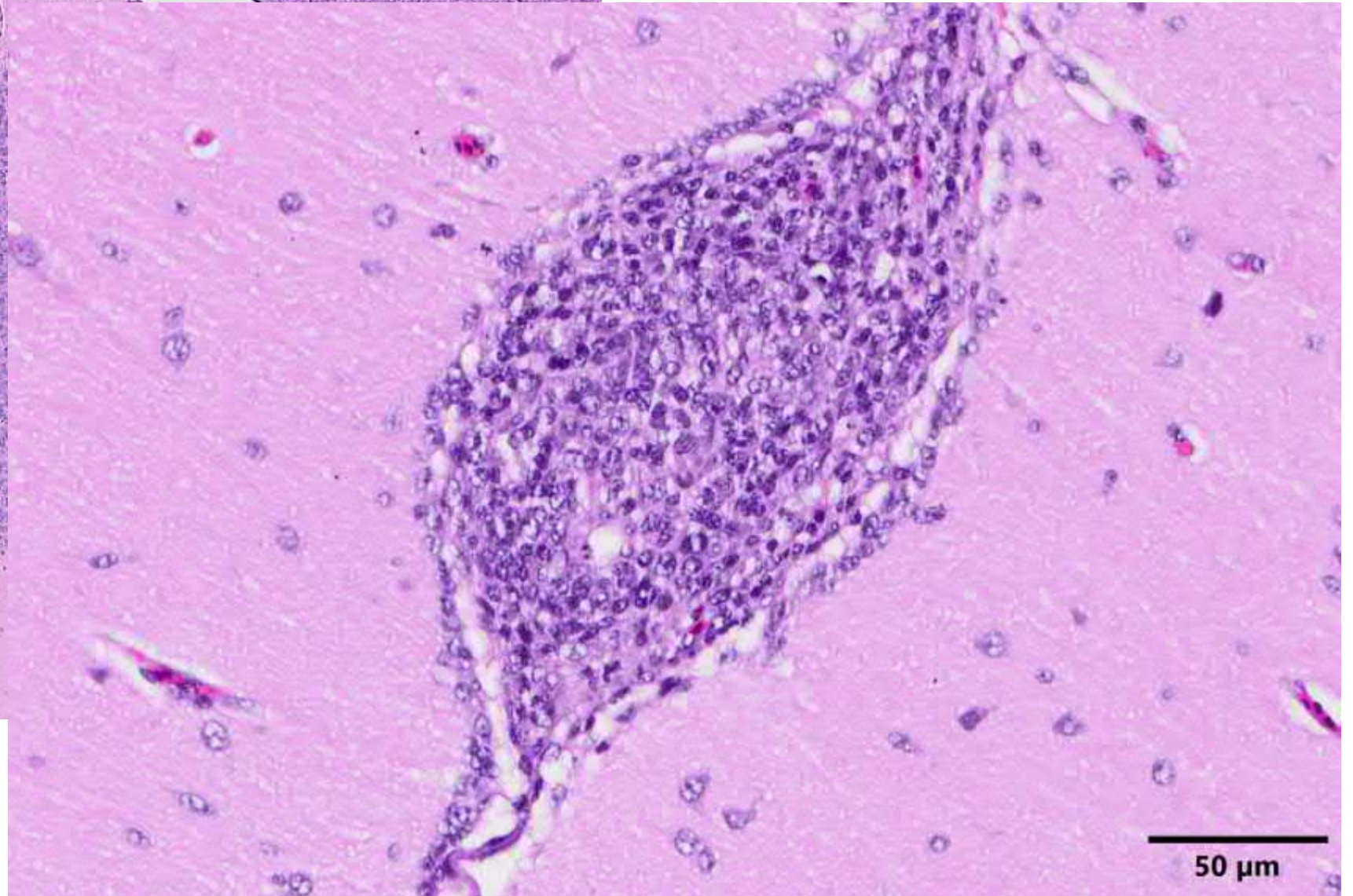
大腦：局部實質壞死、血管周邊水腫



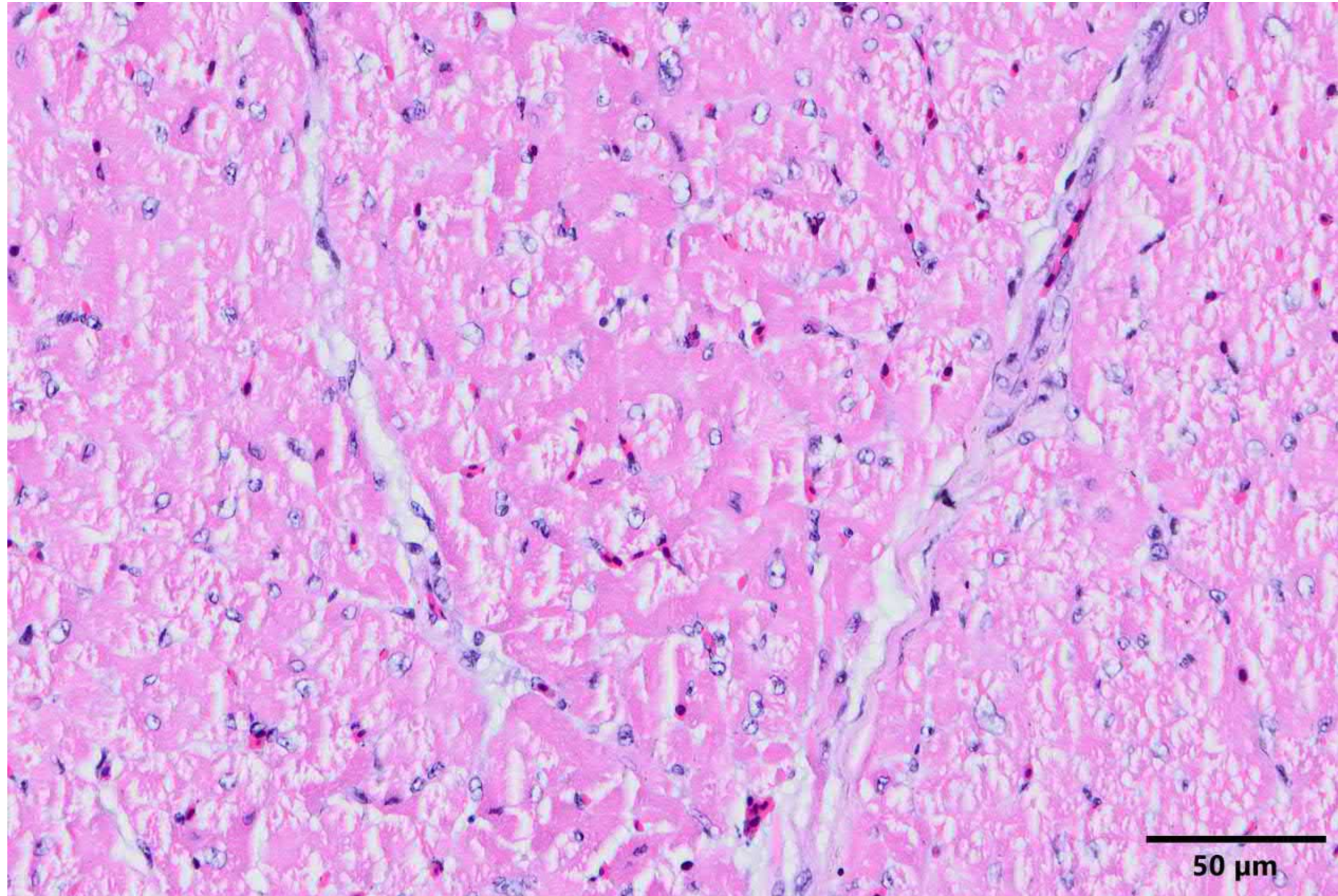
大腦：血管周邊水腫



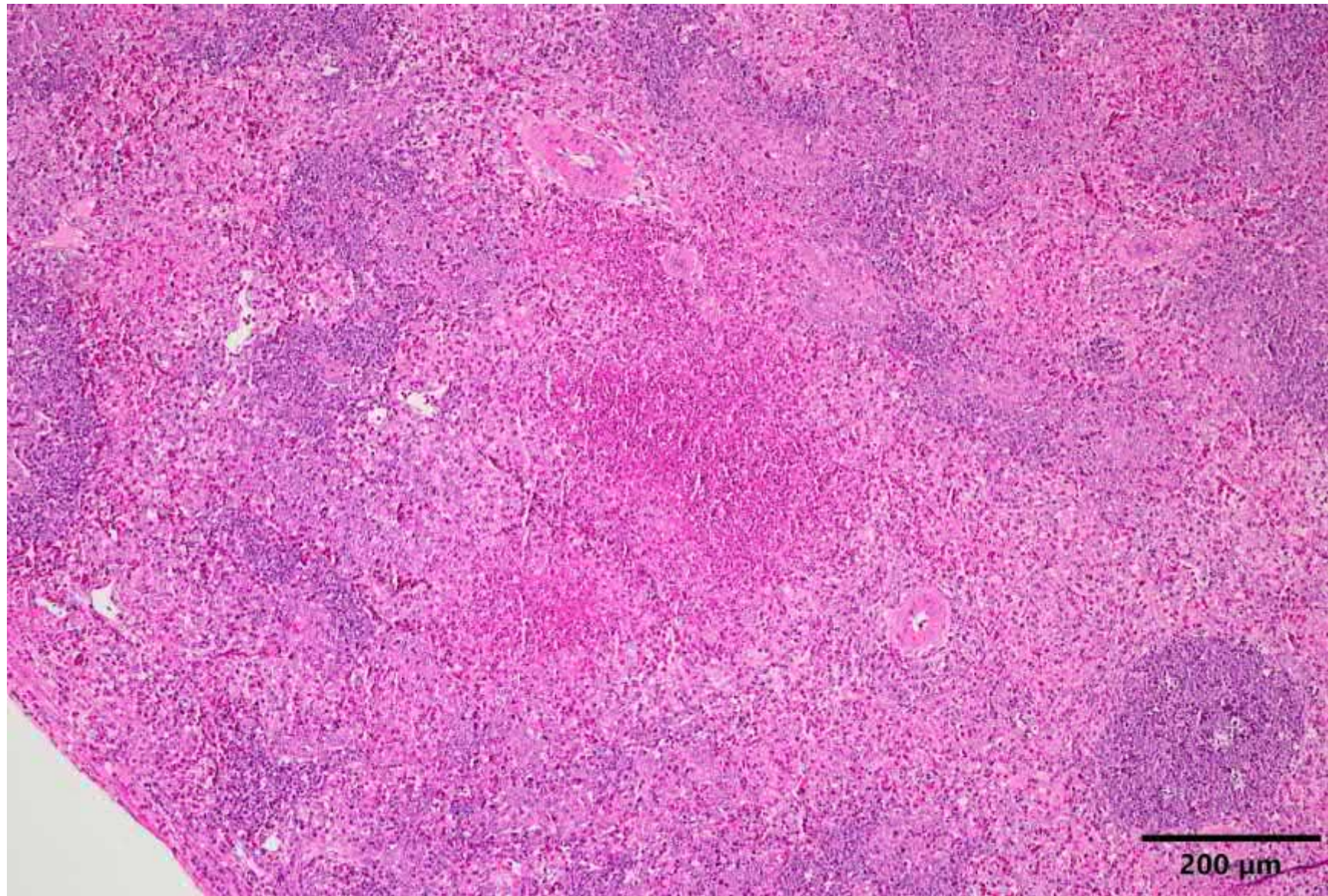
小腦：局部淋巴球性腦膜炎



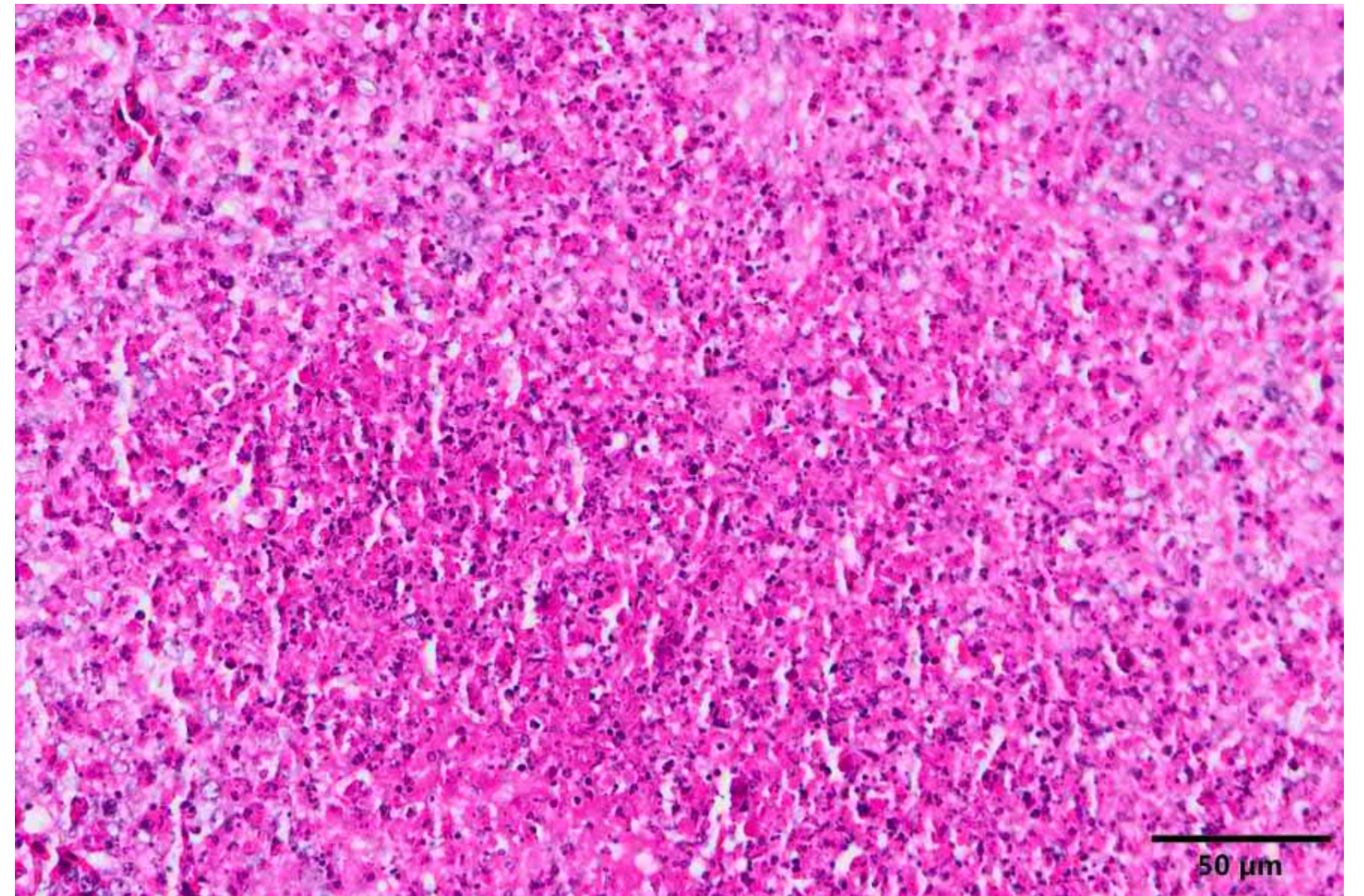
小腦：局部淋巴球性腦膜炎



心肌：局部輕微心肌變性

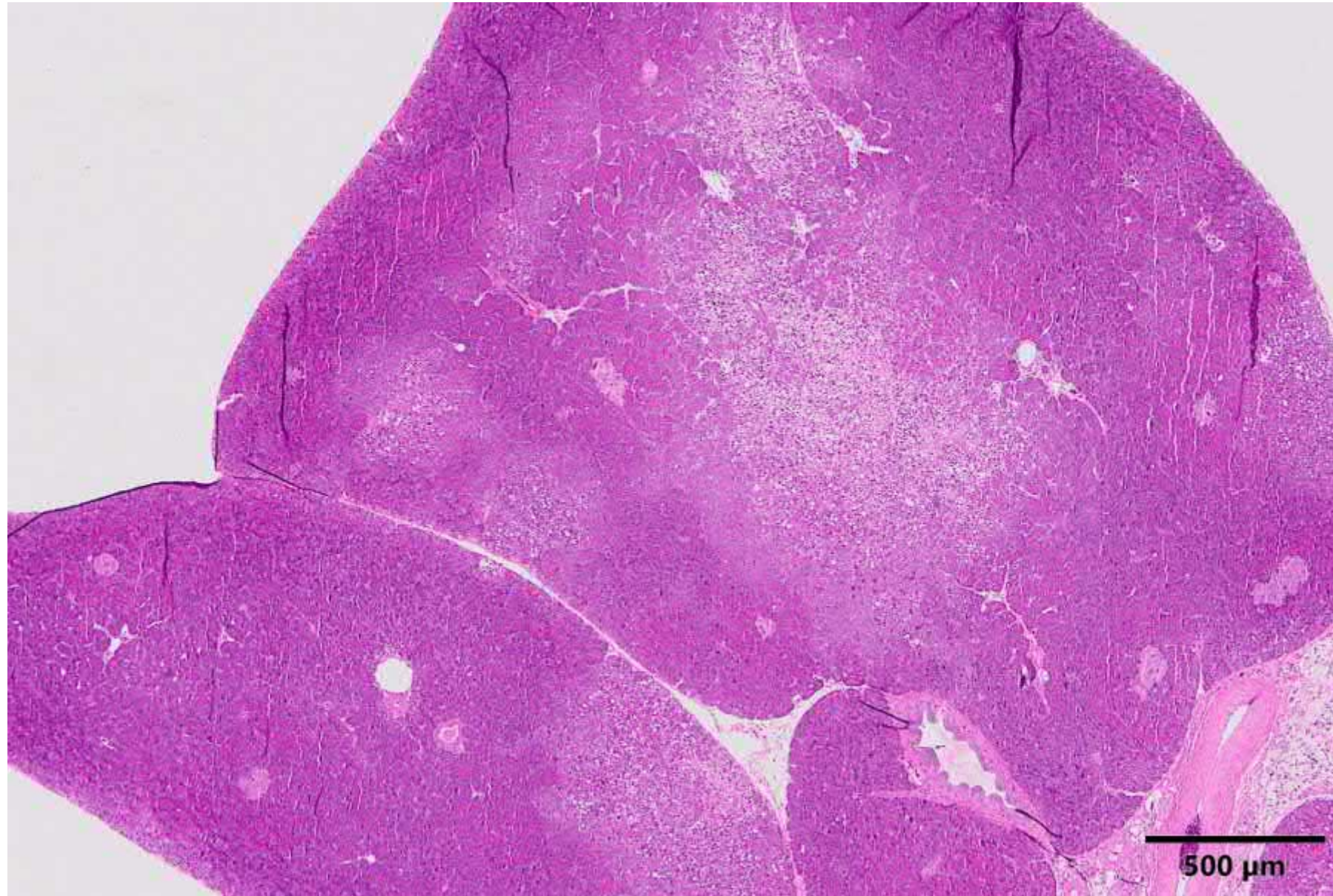


脾臟：局部廣泛實質壞死

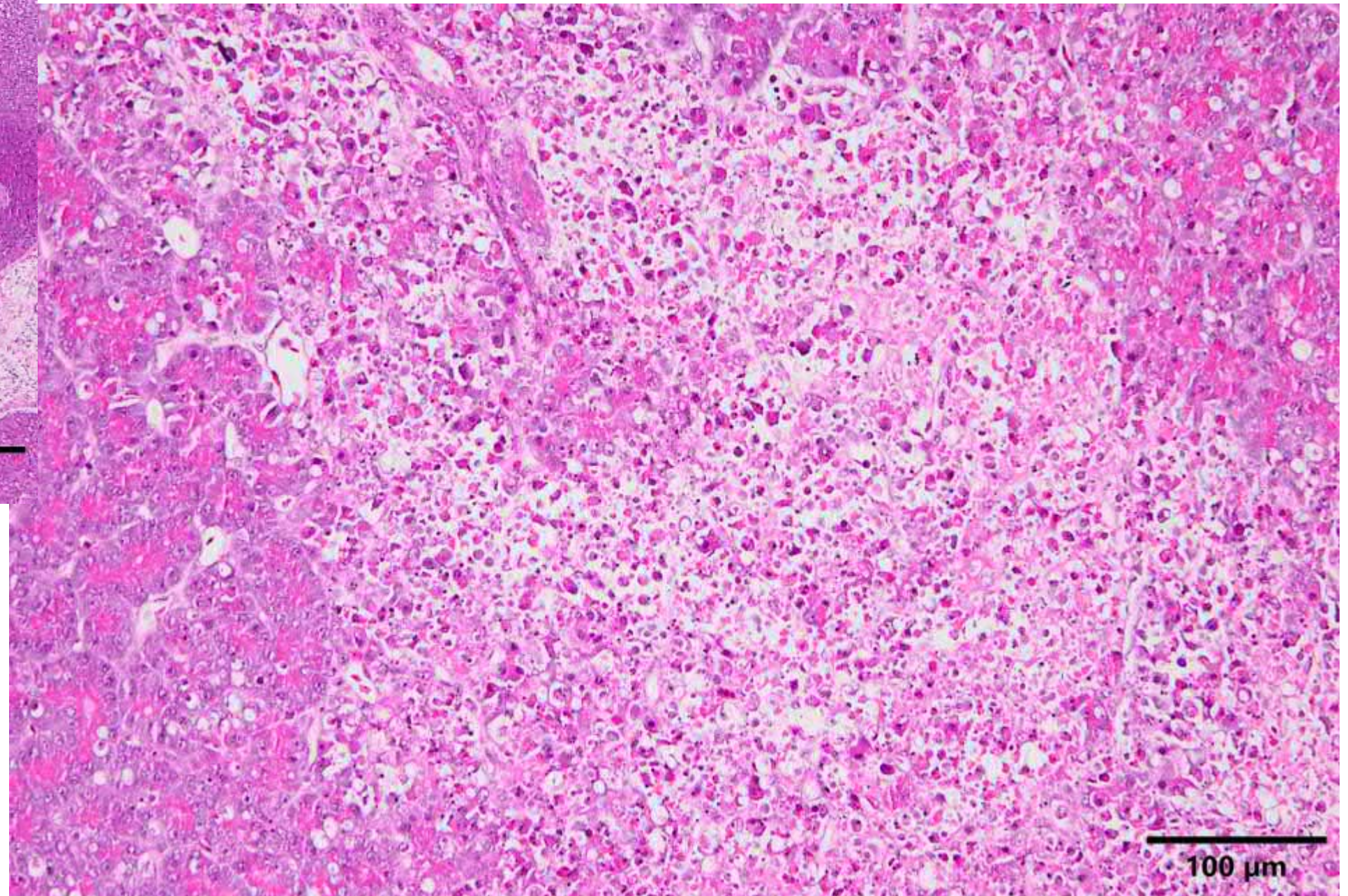


脾臟：局部廣泛實質壞死

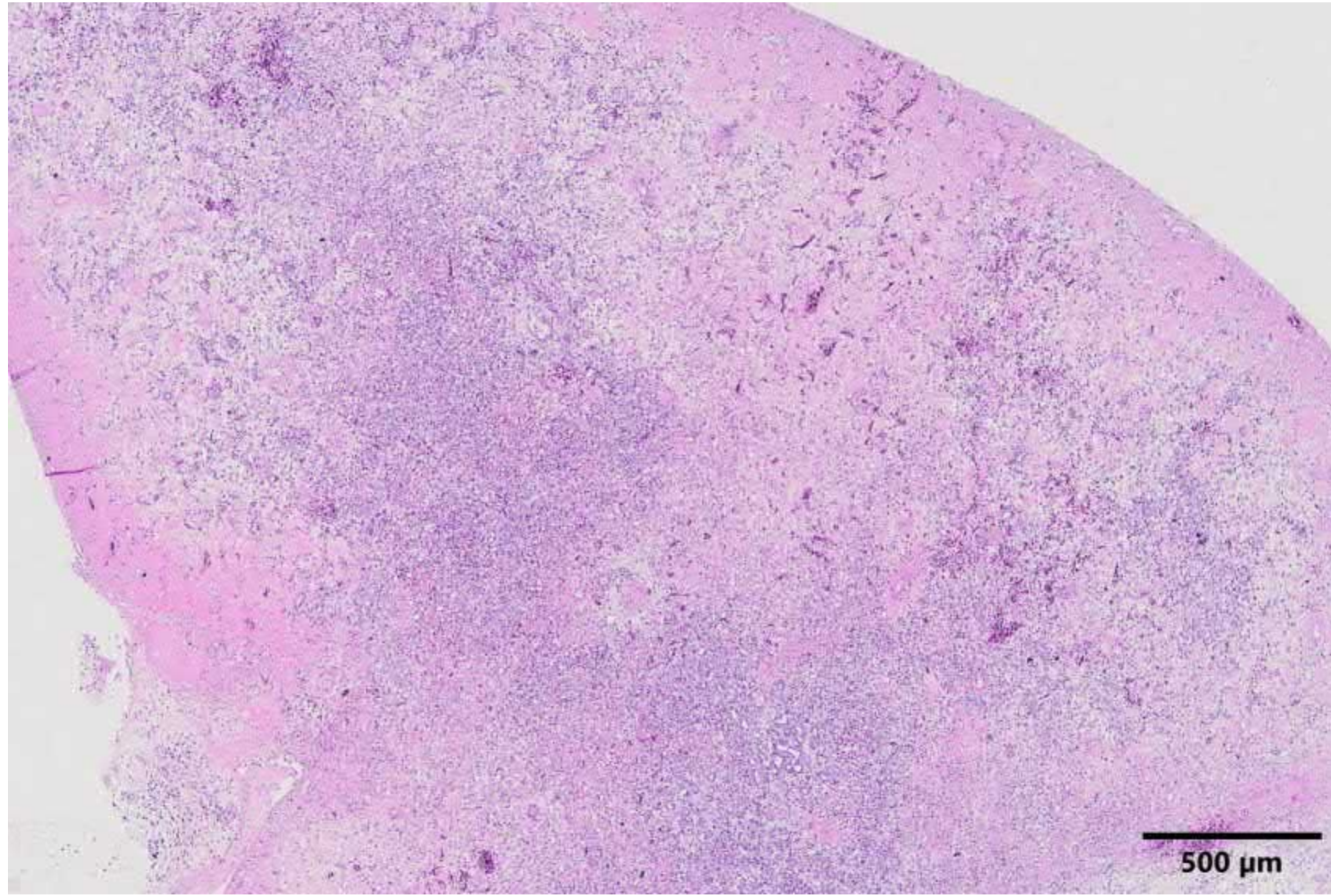




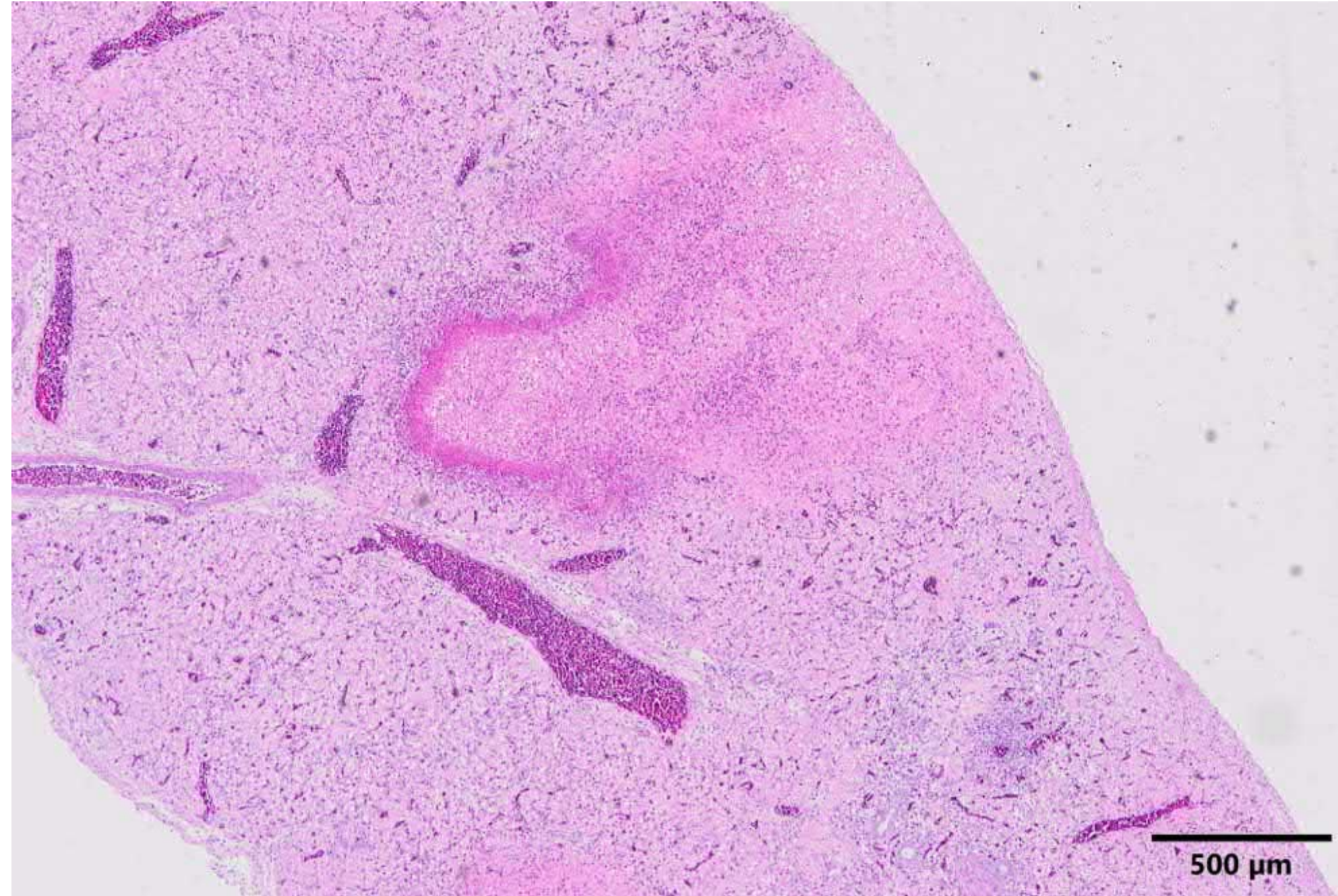
胰臟：多發局部實質壞死



胰臟：多發局部實質壞死



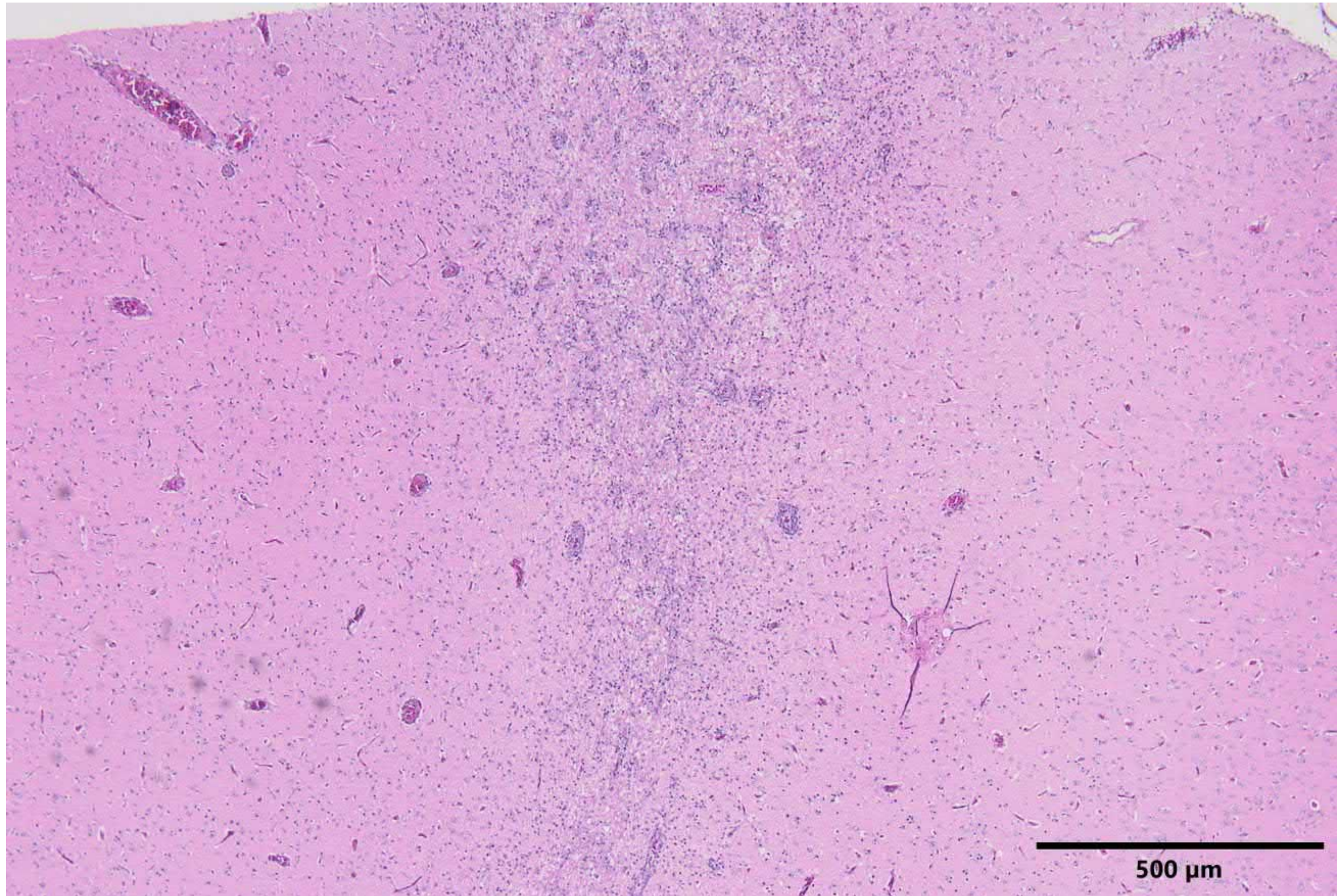
胰臟：嚴重瀰漫實質壞死



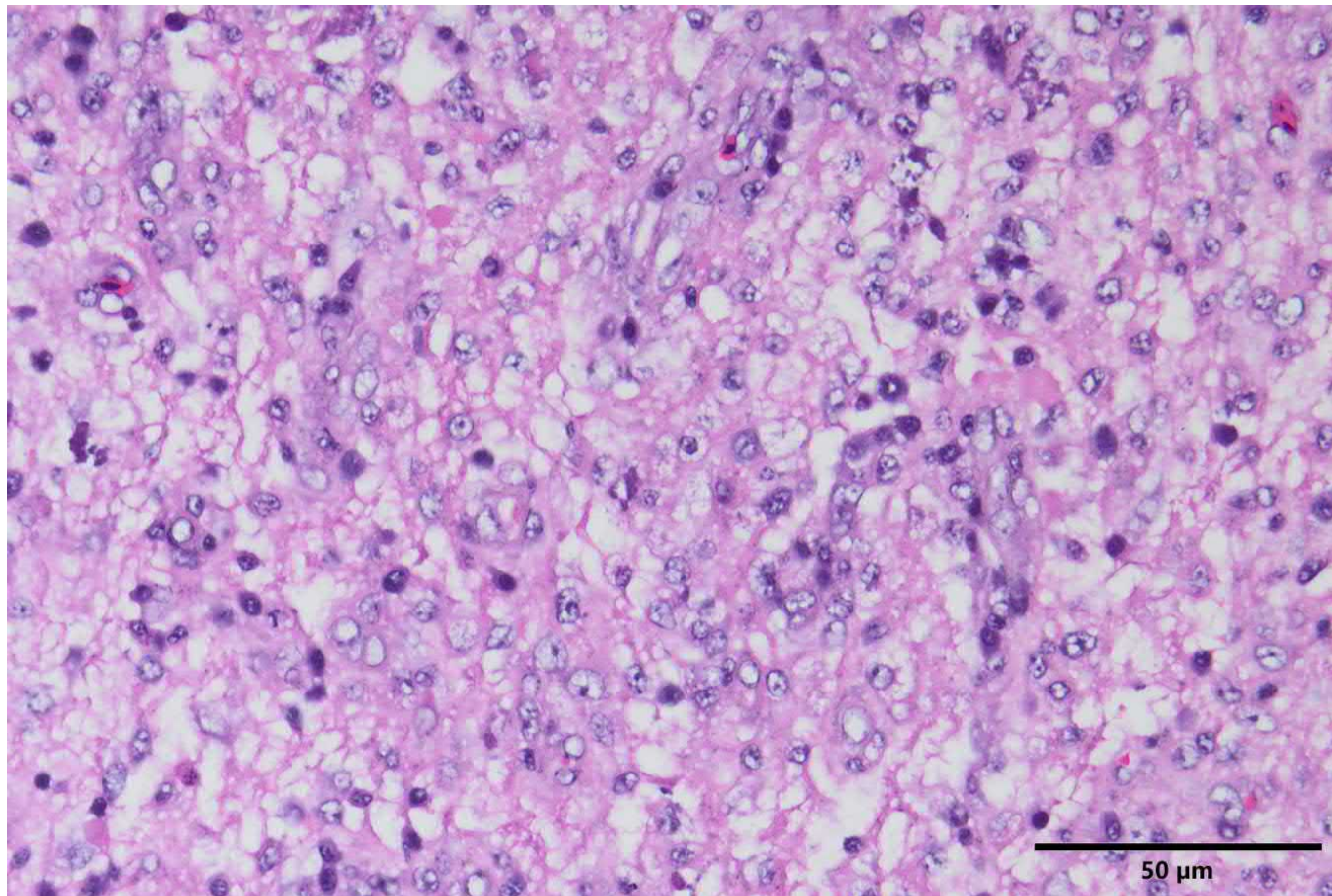
胰臟：嚴重瀰漫實質壞死

# 肉鴨

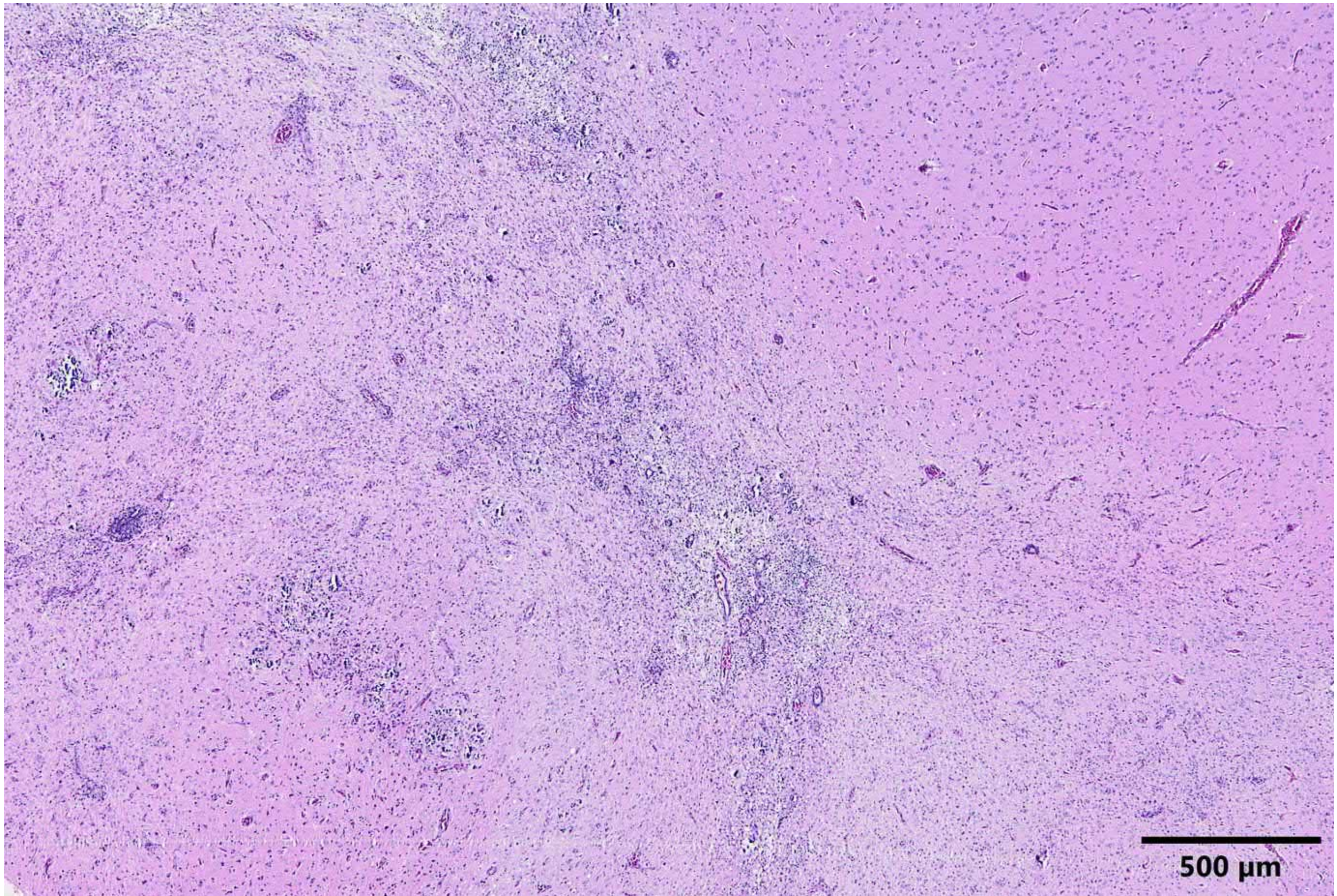
- 臨床症狀與外觀：偶見精神沉鬱
- 常見肉眼病變：胰臟潮紅出血、肺臟濕重、心外膜或心內膜斑駁、腦血管怒、腎腫大



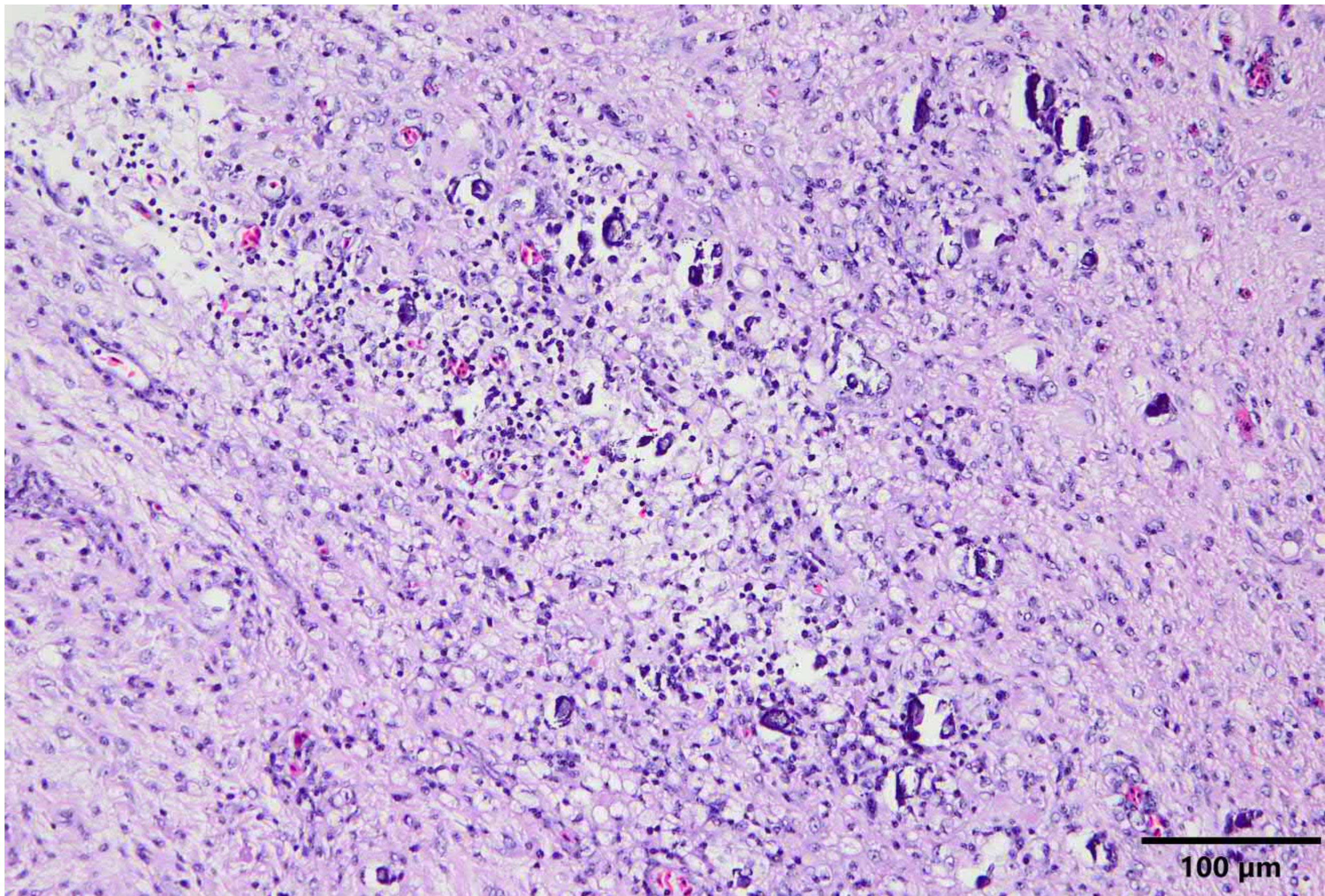
大腦：局部廣泛實質壞死，伴隨gliosis



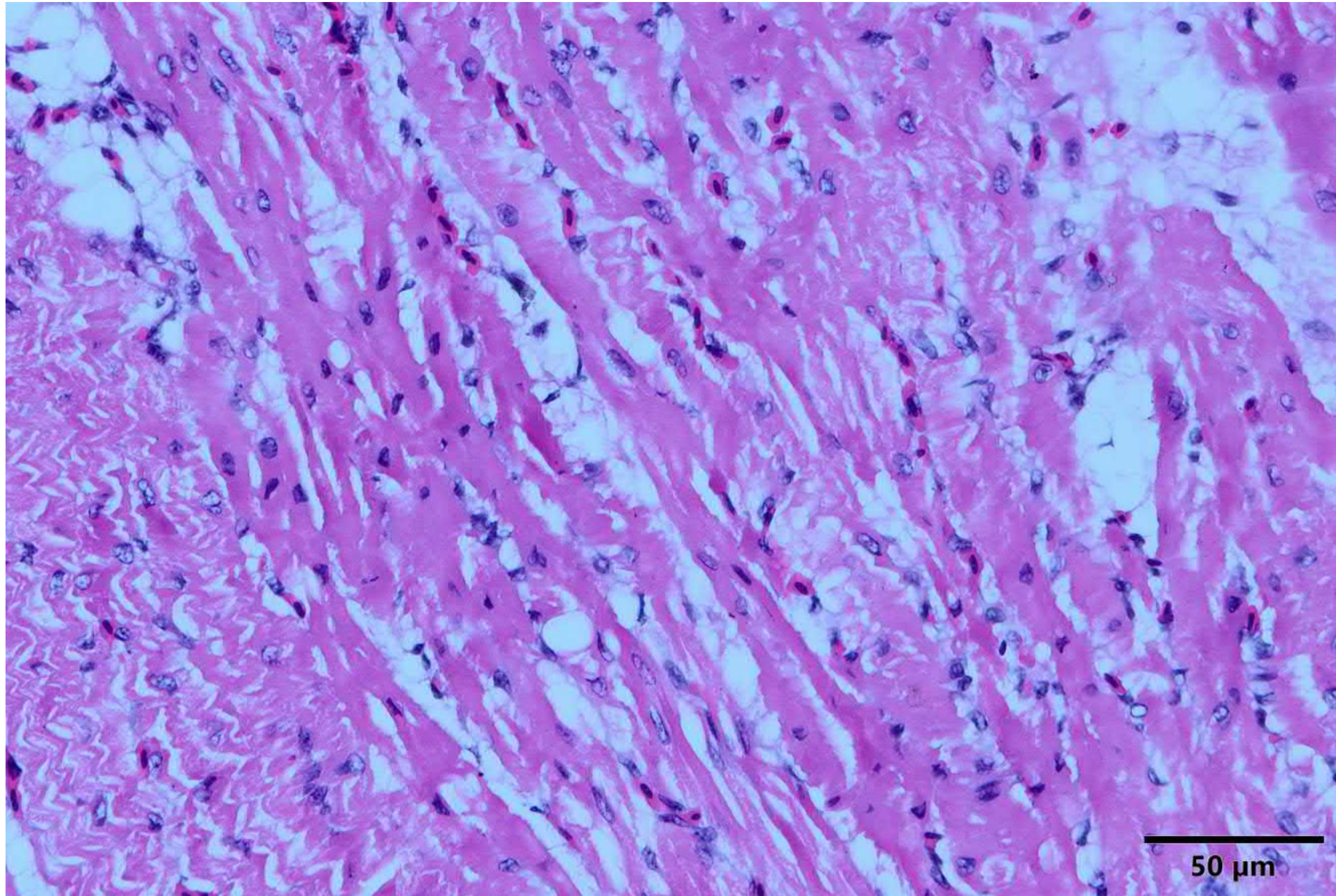
大腦：局部廣泛實質壞死，伴隨嚴重gliosis



大腦：局部廣泛實質壞死，伴隨gliosis



大腦：局部廣泛實質壞死，伴隨礦物質化(mineralization)

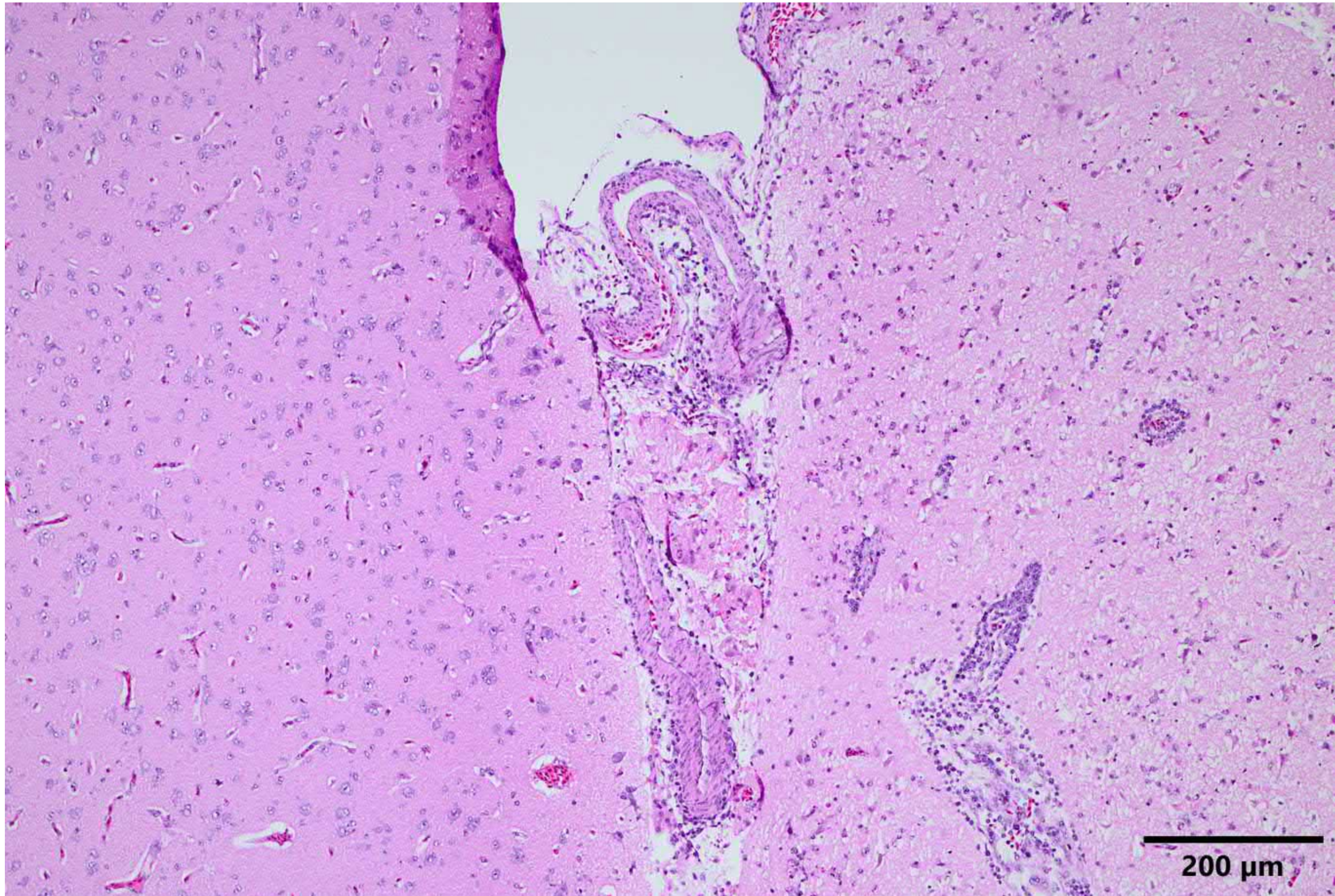


心肌：局部輕微心肌變性



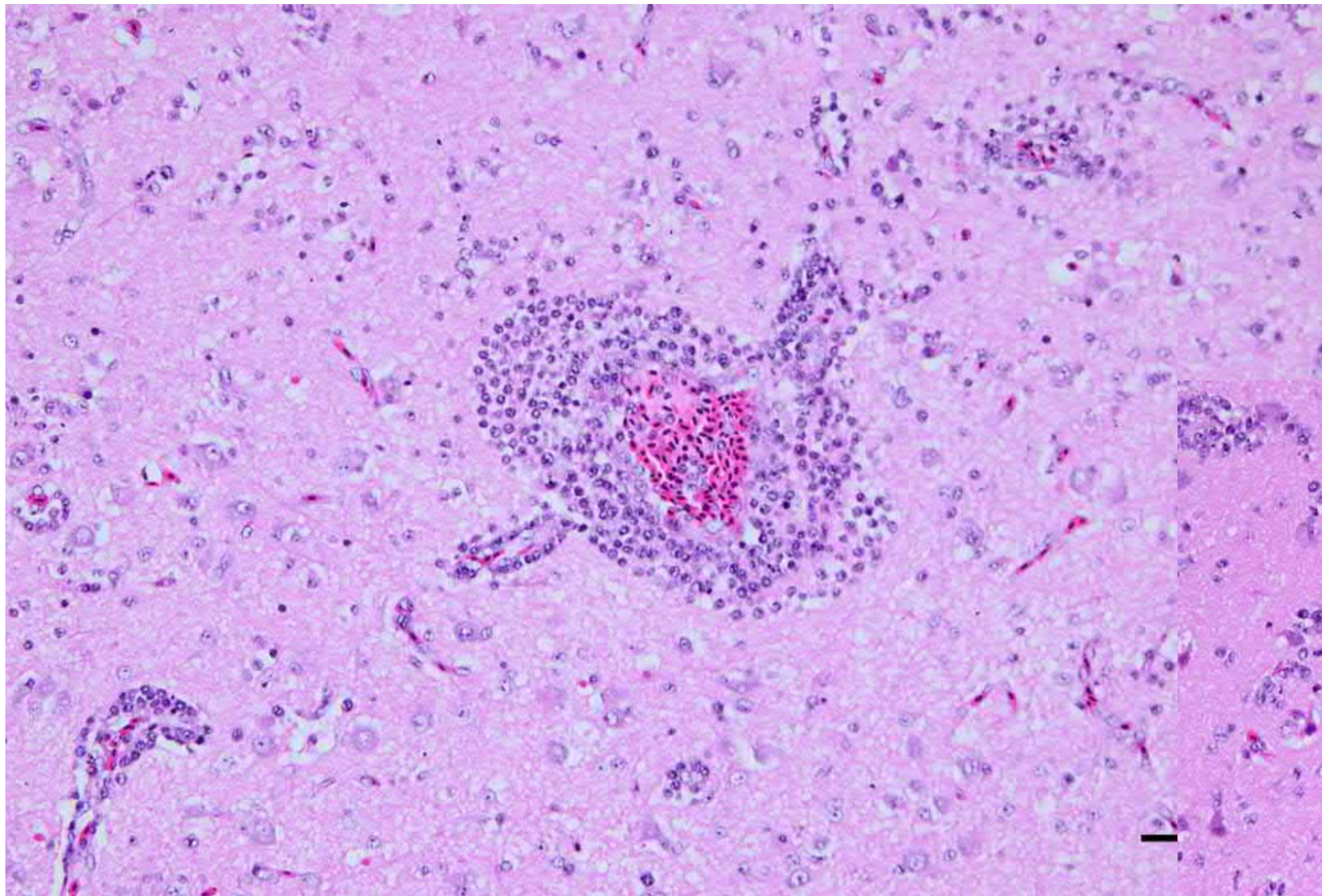
# 鵝

- 臨床症狀與外觀：偶見精神沉鬱
- 常見肉眼病變：胰臟壞死、心臟塌陷、大腦血管怒張、腎腫大、肺臟濕重、氣囊混濁

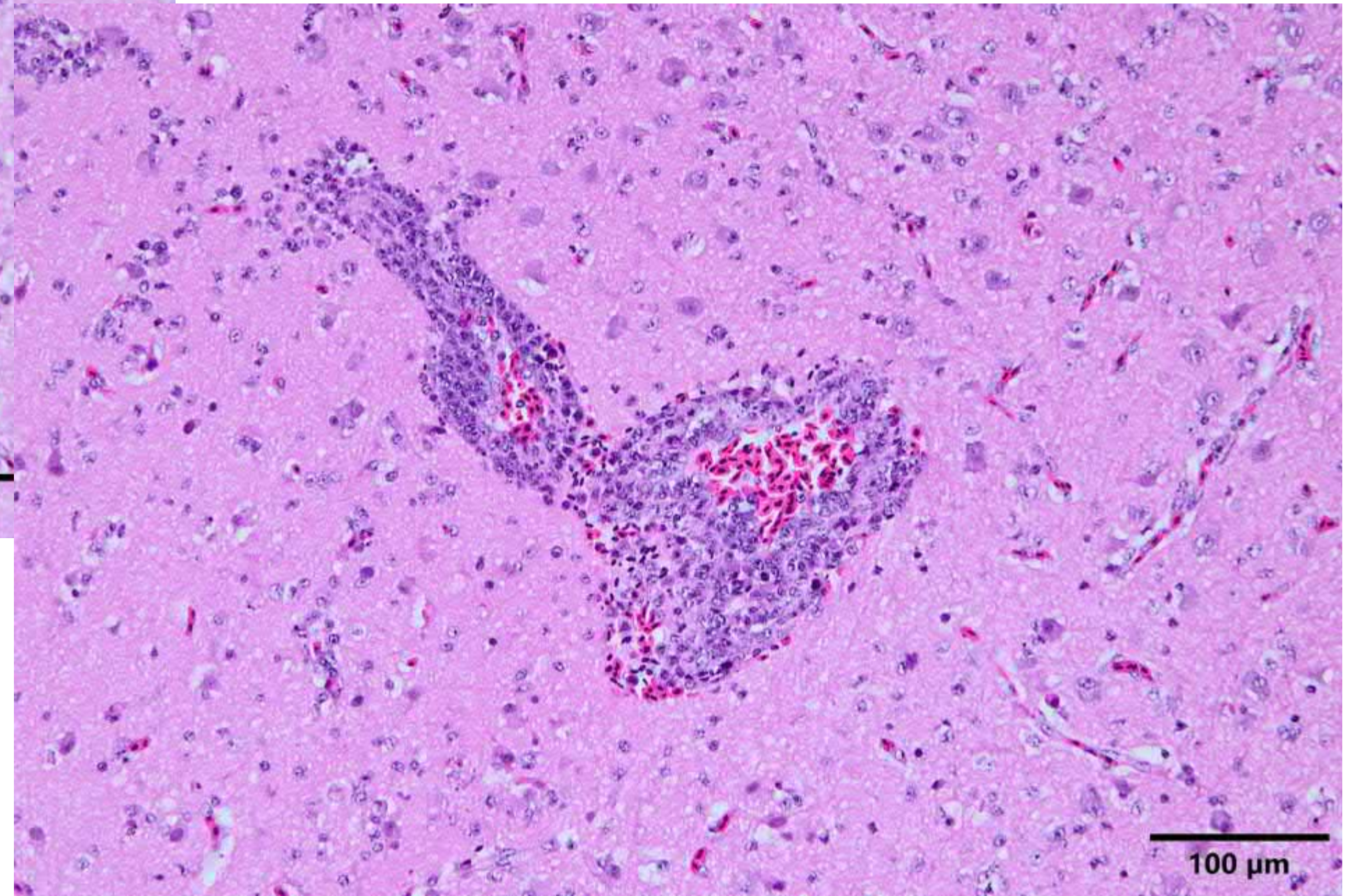


左側大腦：正常

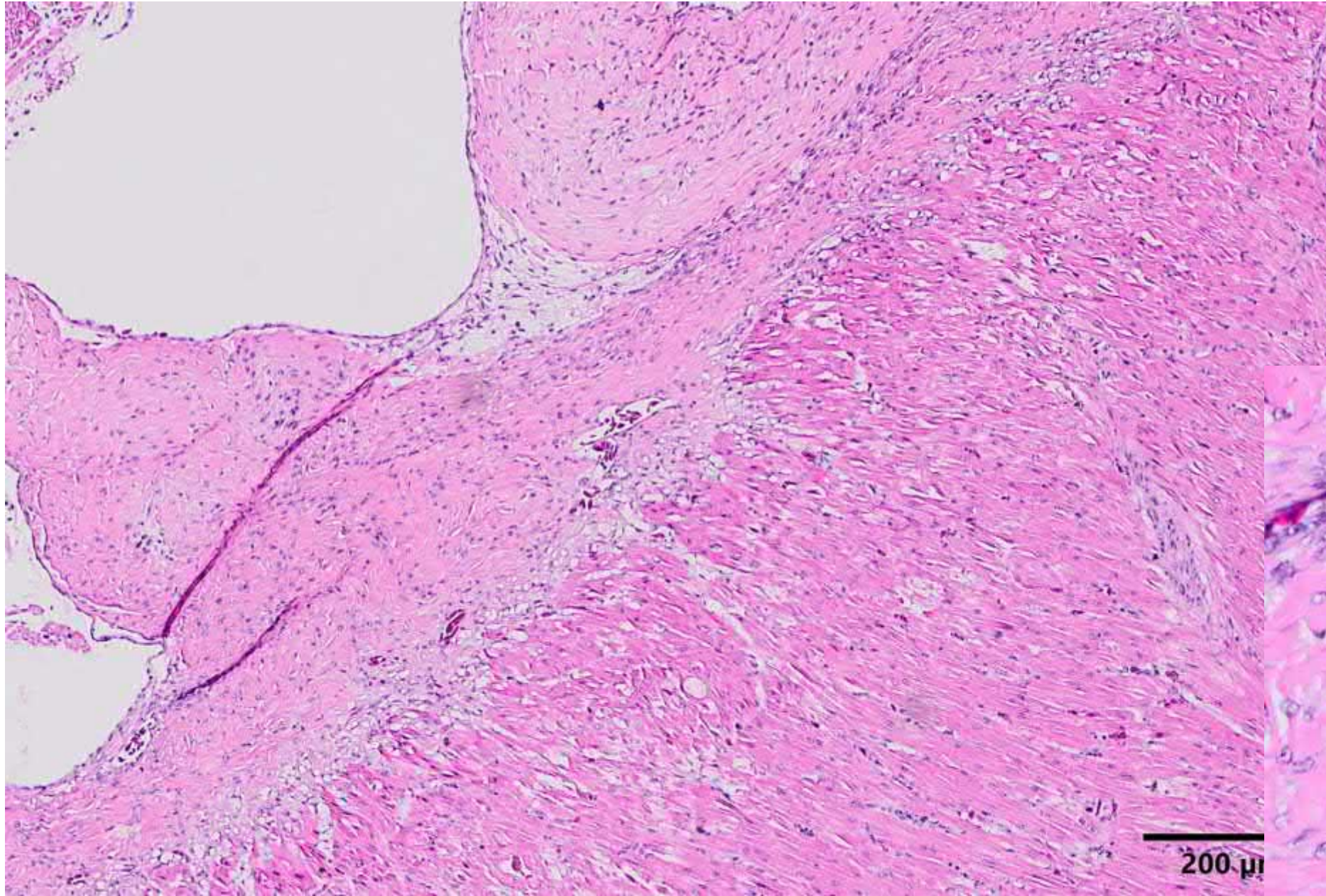
右側大腦：淋巴球性腦膜腦炎。



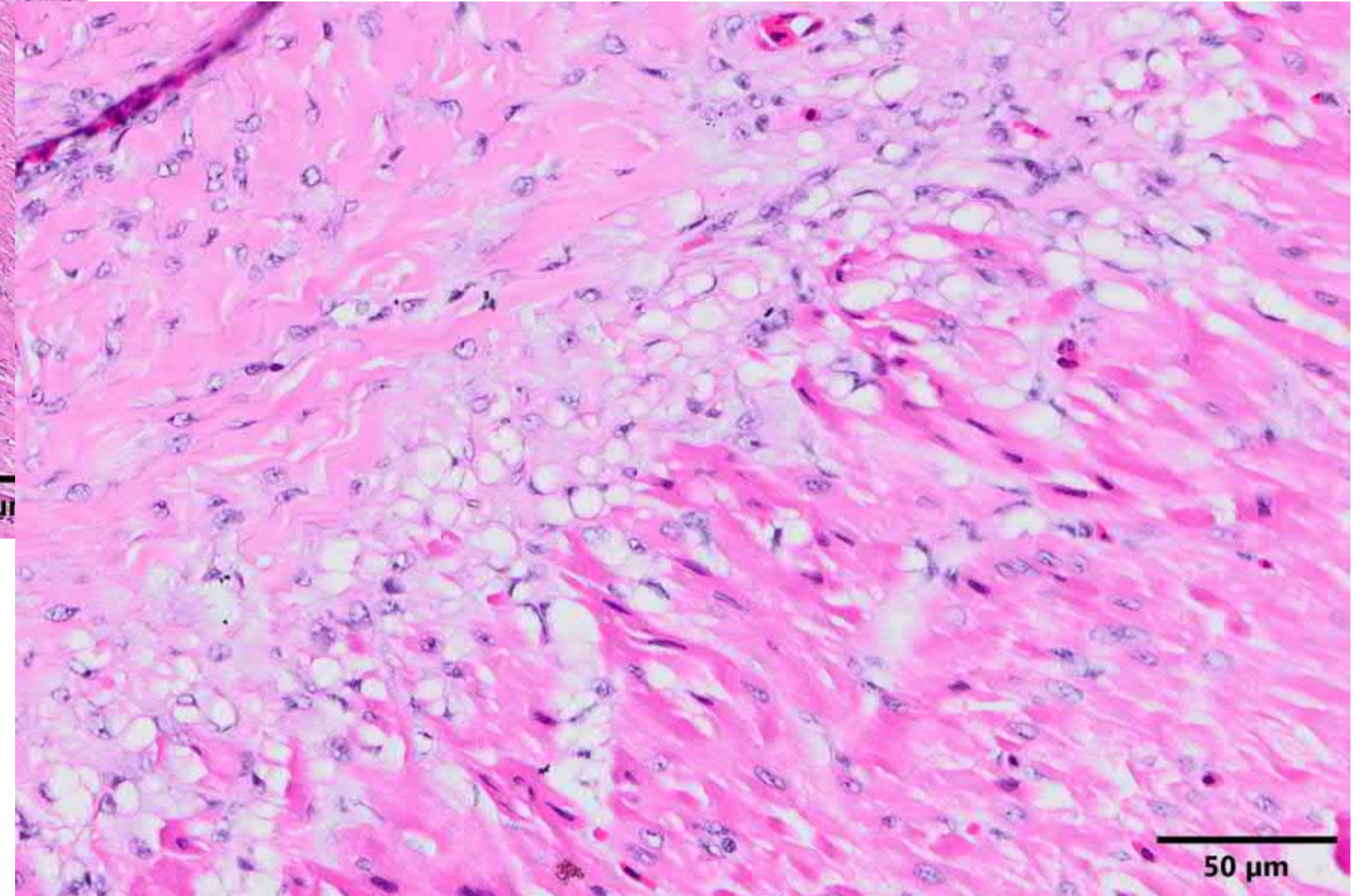
大腦：淋巴球性腦炎



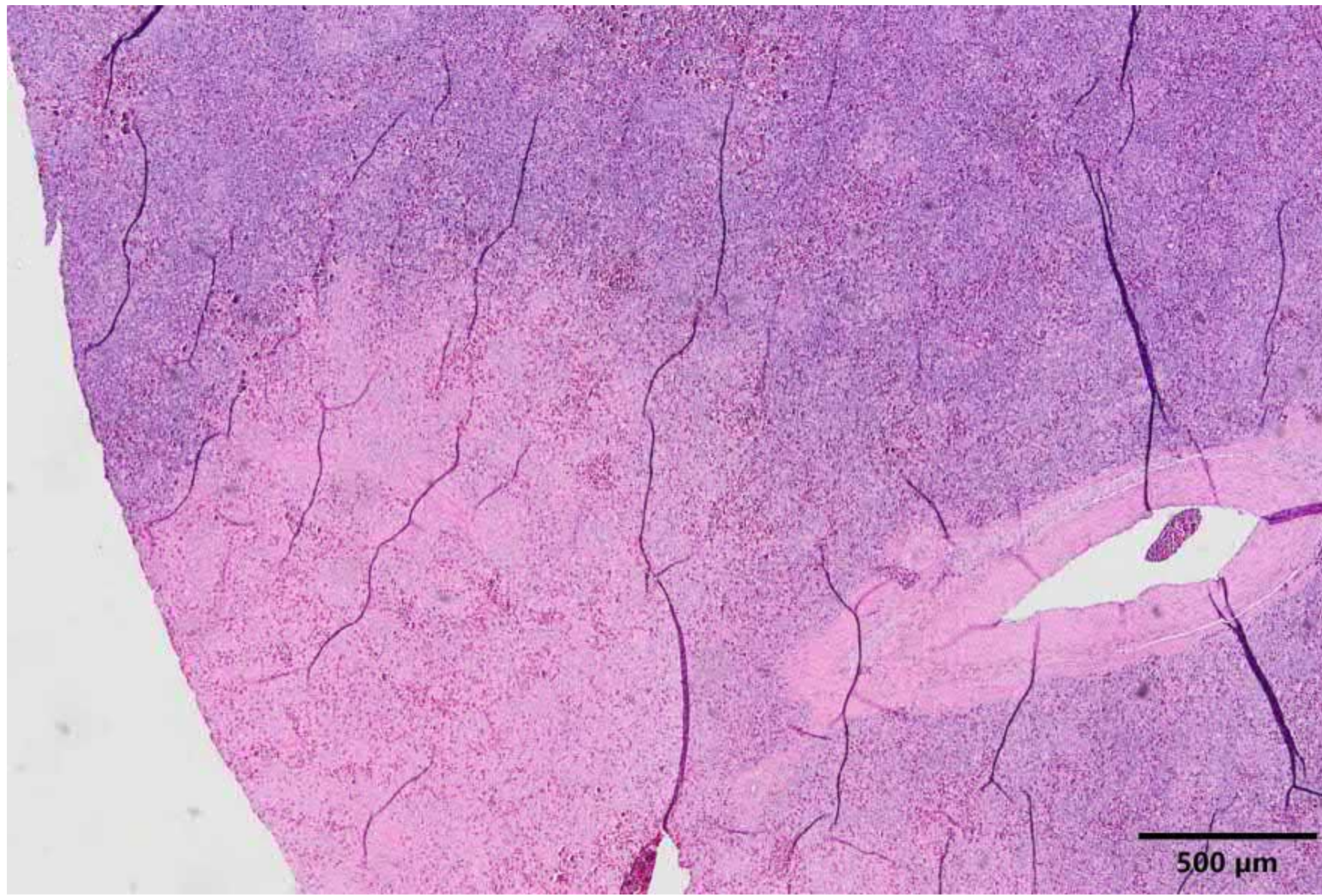
大腦：淋巴球性腦炎



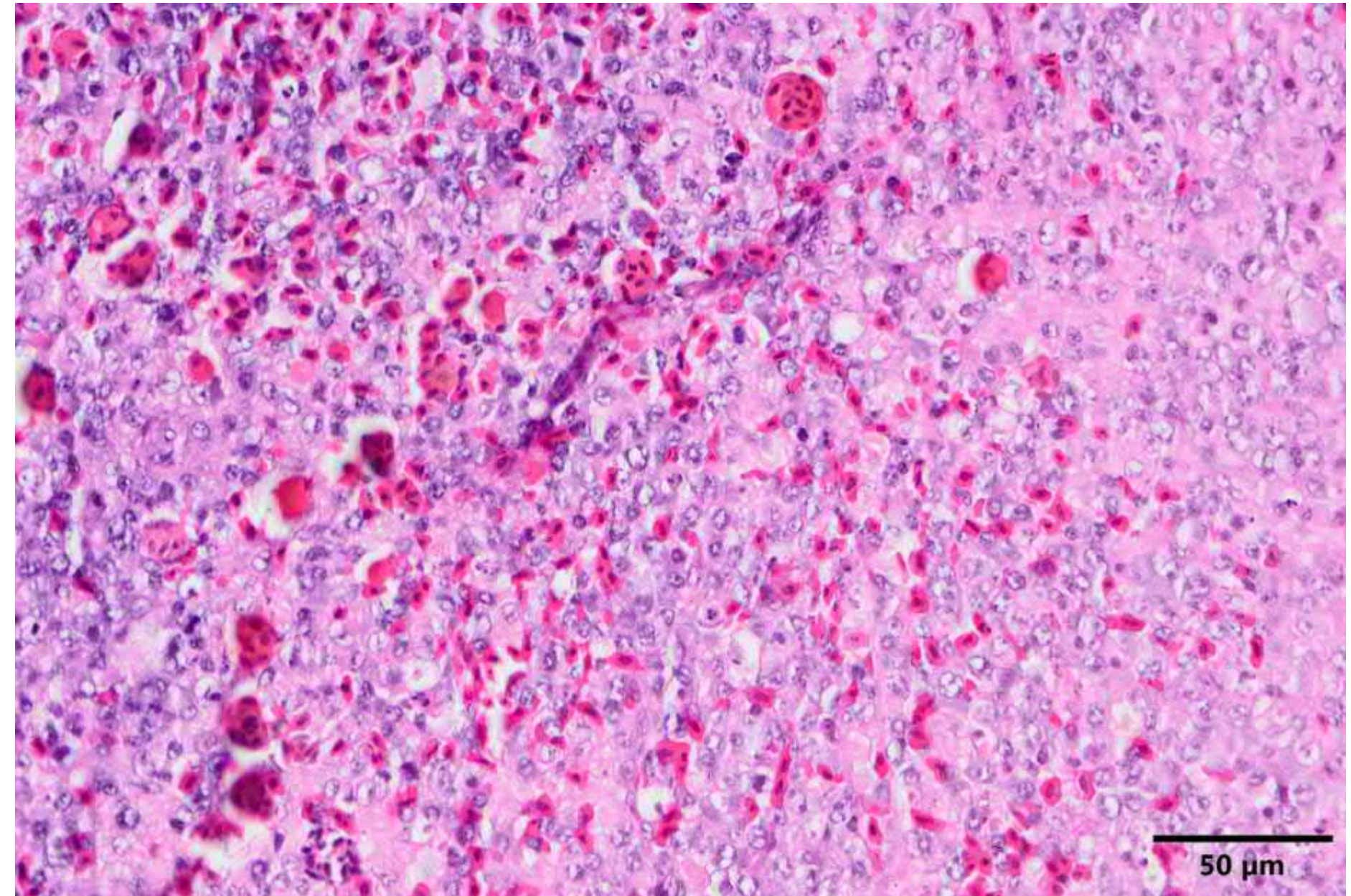
心肌：局部輕微心肌變性



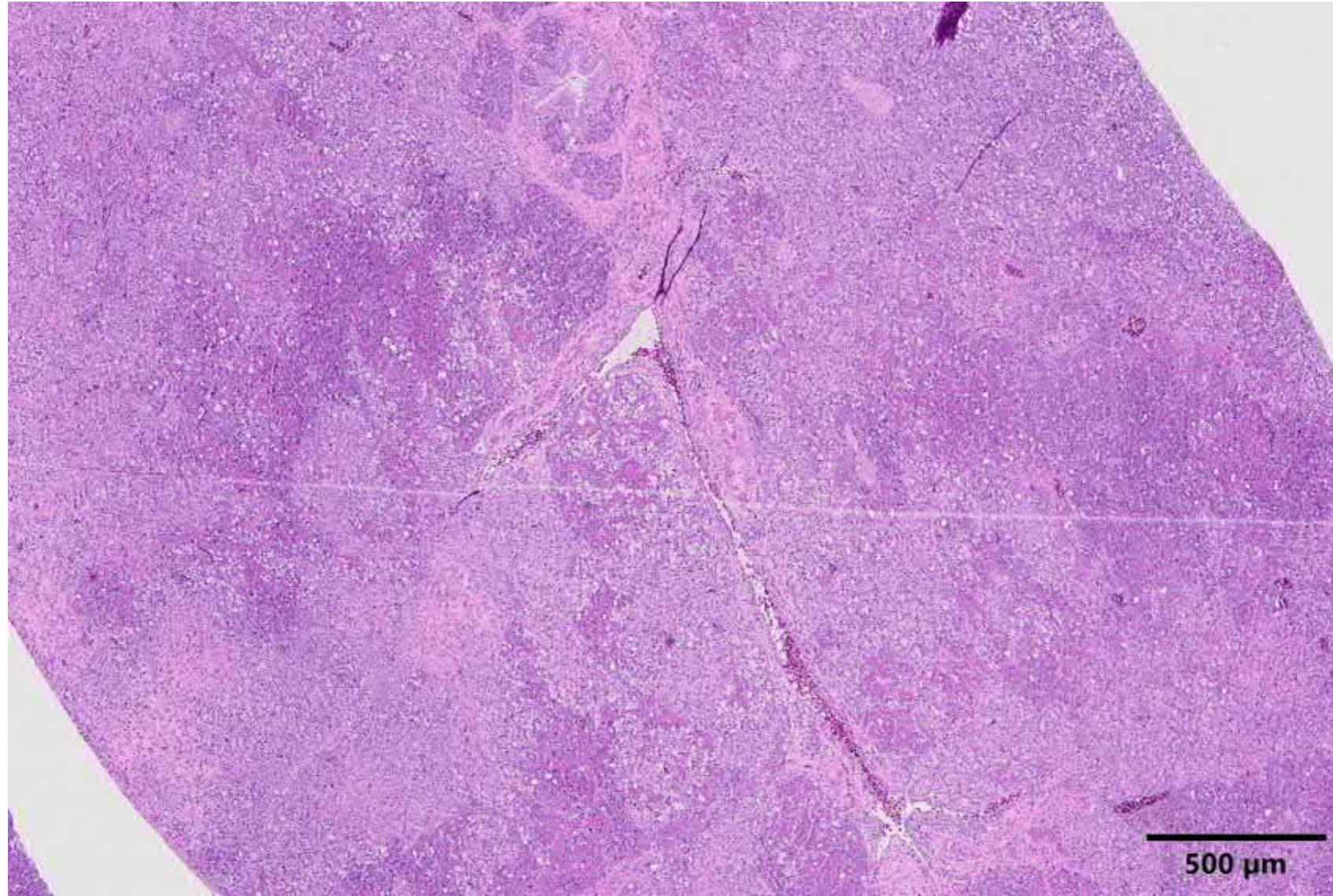
心肌：局部輕微心肌變性



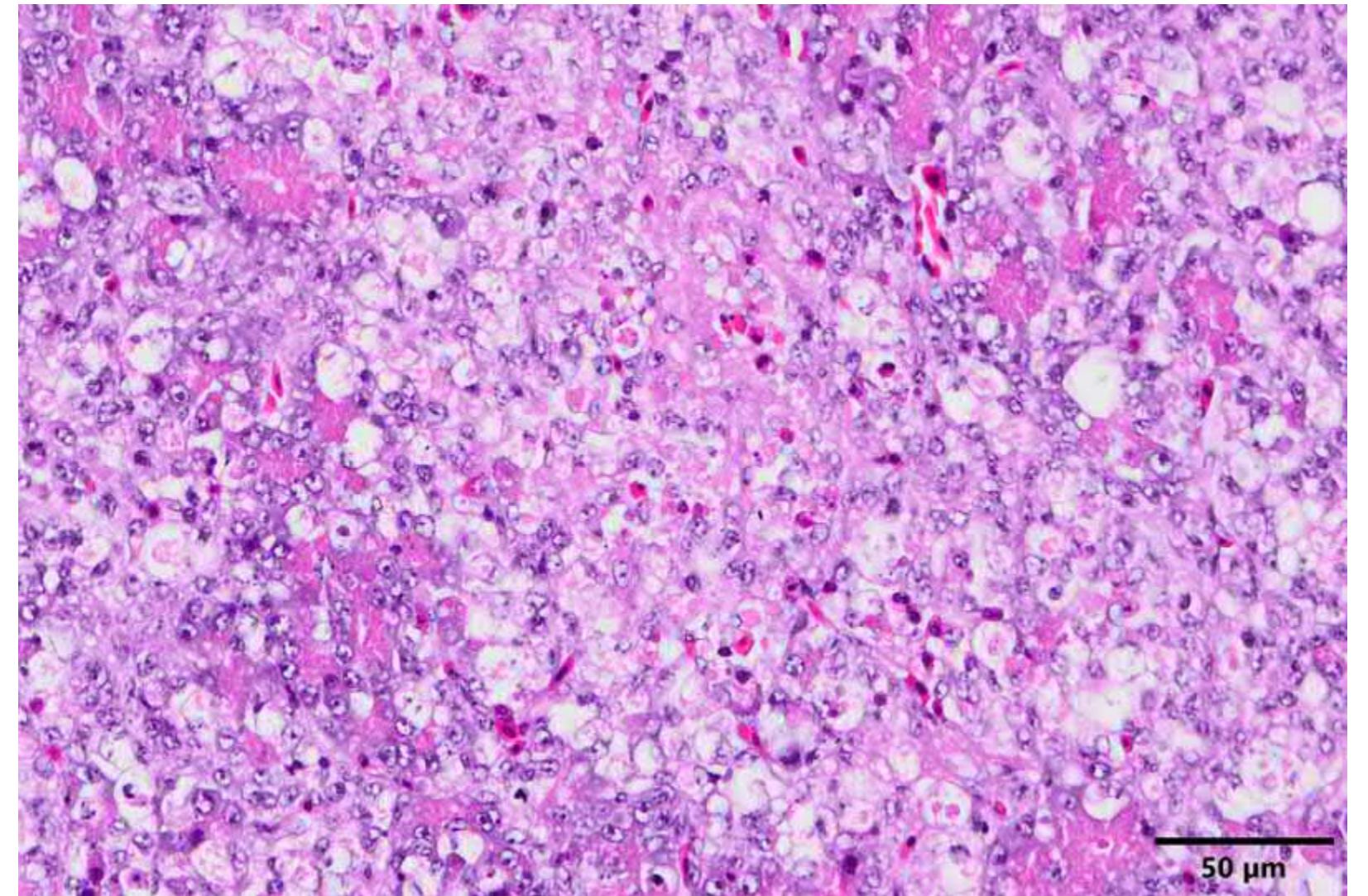
脾臟：局部廣泛實質壞死



脾臟：局部廣泛實質壞死





胰臟：多發局部至融合性實質壞死



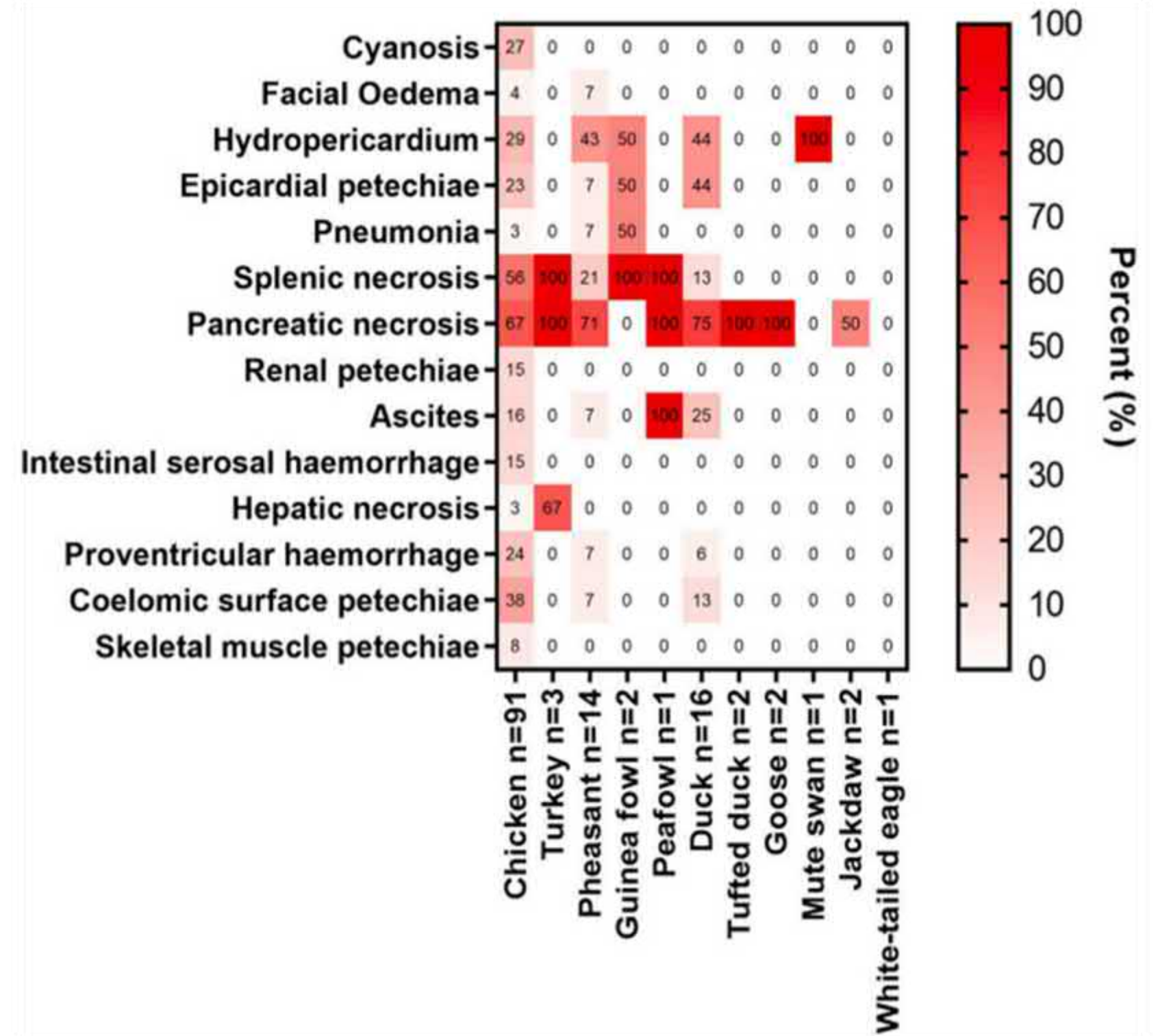
胰臟：實質壞死



# Gross pathology of high pathogenicity avian influenza virus H5N1 2021–2022 epizootic in naturally infected birds in the United Kingdom

Fabian Z.X. Lean<sup>a</sup>  , Ana Gómez Vitores<sup>a</sup>, Scott M. Reid<sup>b</sup>, Ashley C. Banyard<sup>b,c</sup>, Ian H. Brown<sup>b,c</sup>, Alejandro Núñez<sup>a</sup>, Rowena D.E. Hansen<sup>b</sup>

H5N1 clade 2.3.4.4b




# 肉眼病變統計\*

|                          | Chicken | Duck | Goose |
|--------------------------|---------|------|-------|
| Brain congestion         | 22      | 74   | 50    |
| Hydropericardium         | 35      | 16   | 24    |
| Heart collapse           | 21      | 32   | 16    |
| Epicardial petechiae     | 11      | 21   | 3     |
| Endocardium petechiae    | 6       | 5    | 3     |
| Rubbery lung             | 35      | 89   | 39    |
| Liver enlargement        | 14      | 5    | 13    |
| Hepatic congestion       | 9       | 16   | 8     |
| Gastric erosion or ulcer | 9       | 21   | 0     |
| Pale kidney              | 7       | 21   | 3     |
| Kidney enlargement       | 57      | 16   | 34    |
| Pancreas reddening       | 9       | 0    | 21    |
| Pancreas petechiae       | 13      | 11   | 13    |
| Splenic enlargement      | 19      | 32   | 0     |
| Pale foci on spleen      | 21      | 5    | 24    |

Chicken (n=94)

Duck (n=19)

Goose (n=38)



\*以隻數為單位



- 常見肉眼病變多為非特異性，但典型病變（肌腺胃糜爛潰瘍、胰臟出血壞死）亦有機會觀察到
  - 雞：腎腫大、肺濕重、心包囊積液
  - 鴨：肺濕重、腦血管怒張、心臟塌陷、脾腫大
  - 鵝：腦血管怒張、肺濕重、腎腫大

# A Semiquantitative Scoring System for Histopathological and Immunohistochemical Assessment of Lesions and Tissue Tropism in Avian Influenza

Maria Landmann<sup>1</sup>, David Scheibner<sup>2</sup>, Annika Graaf<sup>3</sup>, Marcel Gischke<sup>2</sup>, Susanne Koethe<sup>3</sup>, Olanrewaju I Fatola<sup>4</sup>, Barbara Raddatz<sup>1</sup>, Thomas C Mettenleiter<sup>2</sup>, Martin Beer<sup>3</sup>, Christian Grund<sup>3</sup>, Timm Harder<sup>3</sup>, Elsayed M Abdelwhab<sup>2</sup>, Reiner Ulrich<sup>1</sup>

- Scoring, 0- normal, 1-mild, 2-moderate, 3-severe
- Parenchymal necrosis, necroinflammatory lesions
- Brain, heart, lung, liver, kidney, pancreas, spleen

# 組織病變統計\*

|           | Chicken | Duck | Goose |
|-----------|---------|------|-------|
| Brain, 0  | 0       | 1    | 0     |
| Brain, 1  | 13      | 1    | 2     |
| Brain, 2  | 0       | 1    | 2     |
| Brain, 3  | 0       | 0    | 1     |
| Heart, 0  | 0       | 2    | 1     |
| Heart, 1  | 12      | 1    | 4     |
| Heart, 2  | 0       | 0    | 0     |
| Heart, 3  | 0       | 0    | 0     |
| Liver, 0  | 1       | 1    | 0     |
| Liver, 1  | 5       | 2    | 4     |
| Liver, 2  | 1       | 0    | 0     |
| Liver, 3  | 0       | 0    | 1     |
| Spleen, 0 | 1       | 3    | 0     |
| Spleen, 1 | 5       | 0    | 3     |
| Spleen, 2 | 3       | 0    | 2     |
| Spleen, 3 | 3       | 0    | 0     |

|             | Chicken | Duck | Goose |
|-------------|---------|------|-------|
| Lung, 0     | 1       | 1    | 2     |
| Lung, 1     | 8       | 1    | 2     |
| Lung, 2     | 2       | 1    | 1     |
| Lung, 3     | 0       | 0    | 0     |
| Kidney, 0   | 4       | 0    | 0     |
| Kidney, 1   | 8       | 2    | 4     |
| Kidney, 2   | 0       | 0    | 0     |
| Kidney, 3   | 0       | 0    | 0     |
| Pancreas, 0 | 1       | 0    | 0     |
| Pancreas, 1 | 4       | 3    | 2     |
| Pancreas, 2 | 0       | 0    | 1     |
| Pancreas, 3 | 6       | 0    | 2     |

\*以場次為單位

- 常見組織病變
  - 雞：輕微腦炎、輕微心肌變性、輕微肺炎、輕微腎小管壞死、輕微至嚴重脾臟壞死、輕微至嚴重胰臟壞死
  - 鴨：無或輕微至中等腦炎、無脾臟或胰臟病變
  - 鵝：輕微至中等程度腦炎、輕微心肌變性、輕微肝臟壞死、輕微肺炎、輕微至中等脾臟壞死、輕微至嚴重胰臟壞死

# Discussion

- 現場案例無法排除其他疾病及相關病變（尤其是呼吸道疾病）。
- 後續將進行病毒之免疫組織化學染色，以評估病毒對細胞之親和性。
- 腎臟、心臟常見肉眼病變，但未有明顯組織病變。
  - 後續將進行細胞變性相關的免疫組織化學染色，以分子生物學層面評估細胞之受損程度
- 最終目標為將肉眼病變、組織病變、病毒IHC染色、細胞凋亡IHC染色等結果進行關聯性評估。

**Thank you**